



iJRASET

International Journal For Research in
Applied Science and Engineering Technology



INTERNATIONAL JOURNAL FOR RESEARCH

IN APPLIED SCIENCE & ENGINEERING TECHNOLOGY

Volume: 10 Issue: VI Month of publication: June 2022

DOI: <https://doi.org/10.22214/ijraset.2022.43908>

www.ijraset.com

Call:  08813907089

E-mail ID: ijraset@gmail.com

Image Processing for Alzheimer's disease Detection

Amruth B L, Ms. Sindhu D, Dr. Ravikumar G K

¹Dept. of CSE, BGS Institute of Technology, Adichunchanagiri University, BG Nagar, Karnataka, India-571448.

²Dept. of ISE, BGS Institute of Technology, Adichunchanagiri University, BG Nagar, Karnataka, India-571448

³Professor & Head(R&D), Dept. of CSE, BGS Institute of Technology, Adichunchanagiri University, BG Nagar, Karnataka, India-571448

Abstract: Alzheimer's disease (AD) is a fatal, irreversible brain illness that wreaks havoc on memory and thinking. One of its most significant dementias is Alzheimer's disease. Dementia is the loss of cognitive ability. Image processing is commonly used in medicine to diagnose disorders and assist doctors in making decisions based on observations. This project tries to detect Alzheimer's disease as early as possible so that people can treat it before it becomes irreversible. We present a method for processing axial, coronal, and sagittal magnetic resonance imaging (MRI) of the brain. In a brain MRI, a segmentation algorithm is utilized to highlight lesions. The hippocampus and brain volume are two areas that can be diagnosed with a brain MRI. Individuals with Alzheimer's disease compared to a healthy group with mild cognitive impairment.

Keywords: Dementia, magnetic resonance imaging, Image processing.

I. INTRODUCTION

Alzheimer's disease (AD) is a type of dementia that causes memory loss. The accumulation of beta-amyloid plaques in the brain causes the most frequent forms of dementia. Plaques and tangles are two of the disease's most prominent symptoms. As plaques and tangles accumulate, healthy neurons lose their ability to communicate with each other and finally die resulting in brain tissue shrinkage. The ability to develop new memories is hampered by the death of neurons, especially in the hippocampus. The first part of the brain impacted is the hippocampus. Alzheimer's is a progressive and irreversible illness that develops over time and follows a predictable pattern of brain destruction. It can endure for decades. The condition develops gradually into three stages: mild, moderate, and severe, each with its own set of symptoms and obstacles. The Mild stage lasts for 2 to 4 years on average, during which time a person can function independently but may experience memory lapses. At a moderate level, a person may require assistance with daily activities and may have memory problems.

There is a genetic factor to early-onset AD, and a complicated series of brain abnormalities are involved in late-onset disease. Genetics, lifestyle, and health are other aspects to consider. Alzheimer's disease can be detected by looking for changes in bodily fluids and brain abnormalities. Alzheimer's disease is characterized by abnormal aggregates (amyloid plaques), a twisted bundle of fiber (Tau Tangle), and a lack of nerve cell connection. Ten years after the onset of Alzheimer's disease, symptoms appear.

II. RELATED WORK

This section provides a literature review of previous research that used image processing techniques for AD detection.

The process of obtaining common representations and complex analytical information in the body for medical purposes is known as digital medical imaging. Since proprietary software and expert individuals are required, this is complicated and expensive. Here, we use a program called Matlab, which has a user-friendly interface and is used to detect brain anomalies such as AD in its early stages. These system will display the results of medical image processing, such as magnetic resonance imaging of the brain. A minor structural variation in the brain can develop into a significant disorder, such as Alzheimer's disease. The bicubic interpolation algorithm to employ in our study for initial Alzheimer's disease disclosure and diagnosis.

The MRI scan is also used in image processing to evaluate the chances of early Alzheimer's disease detection. Image processing techniques use for MRI to restore white and grey matter include intensity modification, K-means clustering, and the Area enlarging method. The same method is used to calculate brain volume. The MATLAB software is used to quantitatively and clinically interpret brain MRIs in the axial plane (top view), coronal plane (backside view), and sagittal plane (side view). The technique of obtaining the ROI from an image utilizing automated segmentation methods is known as image processing. An area of expansion, watershed, thresholding, divide & merge, and also the K-means clustering methodology are some image classification techniques.

The segmentation methods indicated are used to detect defects such as porosity, absence of fusion, partial penetration, and wormhole in radiography weld pictures.

This procedure is to locate faulty areas. As a result, they'd often be found in medical imaging, computer vision, optical character recognition, and industrial radiography processing [3]. One of the most commonly used clustering methods is the K-means algorithm. This paper discusses a altered version of k-means method that involves stretching the image to improve its quality. Subjective clustering is a technique for estimating the potential value of a data piece.

3D MRI is more accurate and crucial in detecting Alzheimer's and Parkinson's diseases. Among the algorithms used are the optimization algorithm, the Bat Algorithm, Simulated Annealing, Pattern Search, and Genetic Algorithm. The present strategy is based on the overall amount of brain tissue lost as a result of Alzheimer's disease. The amount of what matter (Tau Tangle) rises as Alzheimer's disease progresses, and brain cells die as a result of a lack of communication between neuron cells. The current technique is calculating the size of the brain using photographs. This view is described using terminologies such as axial plane, coronal plane, and Sagittal Plane. Calculate the grey and white pixel percentages, too. The white pixel percentage is between 65 and 68, the first and second stages of Alzheimer's disease are treatable. This detection approach does not cover cases of Hippocampus atrophy [2]. Alzheimer's disease is detected using the region around the brain, includes the damaged area in the middle of the brain. These include an expanded vascular area and hippocampal damage [3].

III. RESEARCH METHODOLOGY

Figure 1 shows the flow diagram of brain MRI in Alzheimer's disease detection. Several image segmentation algorithms use to recognize brain shrinkage and the Hippocampus brain area throughout this approach. The steps required in processing brain MRI images are depicted in Figure 1.

A. The Brain MRI Input Image

Following the phase-out of ultrasound, the radiological imaging technology Magnetic Resonance (MRI) was introduced. Mri scans were routinely use to detect brain cancers. Magnetic resonance imaging (MRI) technology produces a detailed image of a human biological part. Magnetic resonance imaging is another name for it. Thanks to radio waves and a strong magnetic field, different parts in the body those are previously inaccessible to X-rays, CT scans, and ultrasound are now visible. Tissues, ligaments, muscles, cartilage, and joints can examined by doctors [18].

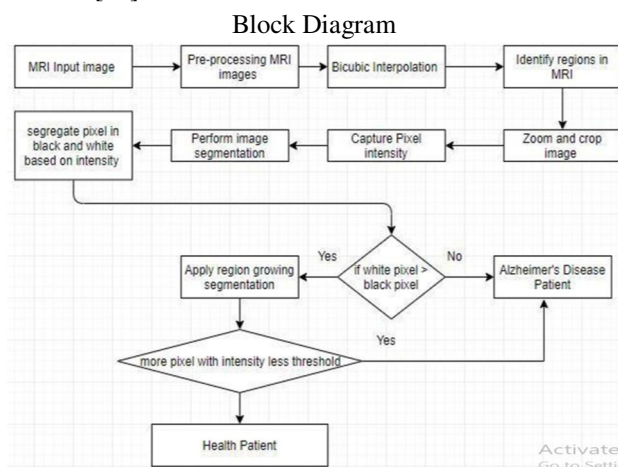


Fig 1: Flowchart

The MRI is processed in this phase using the requisite image segmentation algorithms. This picture segmentation technique method works by enhancing the image's lowest level attributes. It does not necessitate the inclusion of any new aspects, but rather the elimination of any unwanted elements from the image. The image is scaled, converted, and the intensity is adjusted.

B. Interpolation Bicubic

The region in the original brain MRI is not smooth enough to be used for pixel feature detection. Interpolation is a technique for enhancing images such that they are clear enough to be employed in a variety of image processing applications. It is to detect medical MRI images in this case. The interpolated surface is more smooth than the bilinear and nearest-neighbor interpolated surfaces.

C. Region of Interest(ROI)

Determine the ROI for the MRI. AD is detected by looking for atrophy in the hippocampus, brain, and parietal lobe. Fig 2. In the Brain MRI, highlight the region of interest.

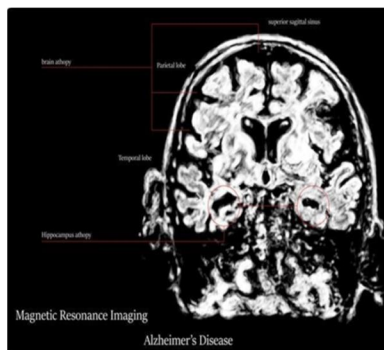


Fig2.Region of Interest

D. Image Segmentation

The region of interest's co-ordinate position is determined, and the selected is cropped and zoomed. The pixel intensity is adjusted using this clipped image. Depending on overall luminance, pixels in compressed images as white or black. The live tissue is in white dead tissue in black. The number of white and black pixels counts, and if the black pixel percentage is modest comparing of the white pixel, the person is said to be healthy. According to the percentage of black pixels present, the person is to have moderate cognitive impairment, AD, is being healthy.

E. Watershed Segmentation

For patients who've been in the early steps of AD, cognitive atrophy is apparent. So, by taking the appropriate medication and altering their lifestyle, the patient can avoid future brain injury. The region-expanding segmentation method to detect brain atrophy. The following is how region-based segmentation works:

- 1) Watershed segmentation performs to the gradient of an image rather than the image itself. The image can transform into three dimensions, and the minimum point for each pixel calculate. The range of brains in Mri images represents in Figure 3.
- 2) Pixels with the same minimum point are grouped, forming a catchment basin. When a water drop lands at a crucial moment, it has an equal chance of failing to more than one minimum.

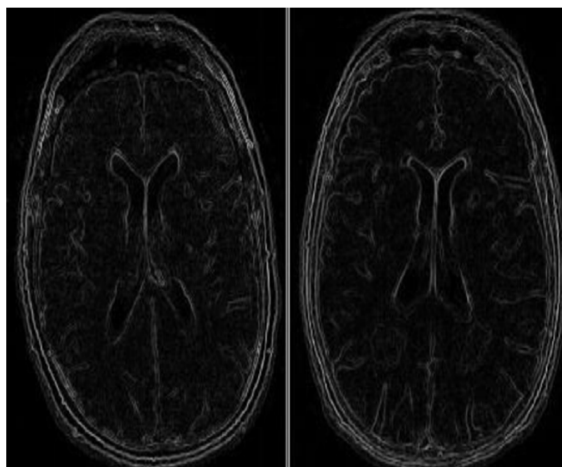


Fig3. Watershed Segmentation was used to create the original image's gradient.

F. Thresholding

Thresholding is one of the most used image segmentation processes. This picture segmentation technique uses pixel intensity segmentation, which divides the pixels into two groups based on their strength. It also supports multilevel thresholding, which allows the classification of pixels into more than two classes.

G. Algorithm

- 1) Accept Magnetic Resonance image as input.
- 2) Alter the input Image data using bicubic interpolation.
- 3) The brain or larger vessel area should be extracted.
- 4) In the retrieved hippocampus and enlarged vessel region, the sum of RGB values on every pixel.
- 5) Consider a black pixel if the sum of the values in the red, green, and blue arrays is zero. Otherwise, treat the pixel as white.
- 6) The cavity region receives a count of black pixels, while the cortex receives a count of white pixels.
- 7) Compare the lengths of the cavity and the cortical region.
 - 7.1 If the cavity region is greater than half of the body, the patient is having stage 2.
 - 7.2 If the cavity region is greater than 30% to 50% pixel, the patient is in stage 1.
 - 7.3 If the cavity region has more than 10% and less than 30%, the patient has MCI.
 - 7.4 If the percentage is less than 10%, proceed to step 8.
- 8) Using the watershed algorithm, produce a gradient picture of the brain MRI. A whole-brain MRI is a good option.
- 9) With a pixel intensity of 0, count every pixel.
 - 9.1 If the threshold is exceeded by a pixel with a pixel intensity of 0. Consider the patient to have disease.
 - 9.2 Otherwise, The patient belongs to the healthy segment.

IV. EXPERIMENT

The study of using Brain MRI to verify the brain atrophy, Hippocampus area, and Vascular Development in those such identification of AD[2, 3, 4, and 5]. Distinct picture segmentation techniques, such as pixel intensity and image gradient, are utilized. This study used 12 MRI samples from Alzheimer's disease patients.

V. RESULT

	PY	PN	
AN	FP=0	TN=0	
AY	TP=1	FN=1	14
	13	1	Total=14

- TPR : $(TP/AY) = (13/14) = 0.9285$
- FPR : $(FP/Actual\ No) = (0/0) = 0$
- Accuracy : $(TP+TN)/Total = (13+0)/14 = 0.9285$
- Precision : $(TP/PY) = (13/13) = 100$
- Exactness : $(TN/AN) = 0$
- Prevalence: $(AY/Total) = (14/14) = 100$
- Misclassification Error : $(FP+FN)/Total = (0+1)/14 = 0.0714$

VI. CONCLUSION

Use in image processing to diagnose Alzheimer's disease early proved successful. Vascular enlargement and brain atrophy The identification of enlarged Vascular is achieved using picture segmentation. The size of the enlargement determines whether the patient is healthy, in the first stage of AD, in the second stage of AD, or in the third stage of AD or the mild phase of cognitive impairment. Brain shrink is another crucial factor in detecting Alzheimer's disease. Brain atrophy is recognized using the Watershed image segmentation algorithm. The Cavity in Brain Atrophy can check using the picture gradient. This automated technique has a straightforward methodology and a minimal image time complexity. It also solves the problem of earlier detection while causing minimal brain harm. It will help to advance medical imaging studies.

VII. FUTURE WORK

Only one image can be detected at a time using the following procedure's output. The number of Alzheimer's disease, MCI, and healthy patients can be scanned and detected using an image database or picture repository as an input to the procedure. It is used instead of image processing to detect life-threatening diseases. Support vector machines and deep learning principles are examples of machine learning algorithms such as convolution neural networks can deliver more accurate and superior results.

REFERENCES

- [1] "Image segmentation of radiography images: an analysis." Volume 5, Issue 11, November 2012, B. Karthikeyan, V. Vithiyathan, B. Venkataraman, M. Menaka, V. Vithiyathan, B. Venkataraman, V. of the Indian Journal of Science and Technology. ISSN-0974-6846.
- [2] "Using the k-means clustering technique with the subtractive clustering algorithm to segment images, Nemirakpam Dhanchandra, Yembem Jina Chanu, Khumanthem Manglem " 764-771 11th International Multi-Conference on Information Processing (IMCIP2015). ELSEVIER
- [3] IEEE International Symposium on Biomedical Imaging, 11th Edition (ISBI). 31st July 2014. ISSN-1945-8457, Siqi Liu, Sidong Liu, IEEE Student Member, Weidong Cai, IEEE Member, Sonia Pujol, Ron Kikinis, Dagan Feng, IEEE Fellow "Early Diagnosis of Alzheimer's Disease using Deep Learning" 2014.
- [4] International Journal of Engineering and Technology Research. Rohini, eISSN:2319-1163|PISSN:2321-7308 "Brain Tumor MRI Image Segmentation and Detection in Image Processing," by Paul Joseph, C. Senthil Singh, and M. Manikandan.
- [5] "Image Processing Techniques for Detection of Brain Abnormalities in Alzheimer's Disease," Anitha Raju, S. Jyothi, and P. Ramesh Babu
- [6] <https://www.nia.nih.gov/health/alzheimer-s-disease-fact-sheet>
- [7] Asmiya Naikodi, Nida Fatima, Shamili.P, and Neha Gopal.N "Image processing and MRI scanning for early identification of Alzheimer's disease." Volume 3, Issue 9, May 2016, International Journal for Technological Research in Engineering. ISSN:2347-4718.
- [8] Members of the IEEE Computer Society include John Martin, Alex Pentland, Stan Sclaroff, and Ron Kikinis. "Shape Deformations in Neuropathology: Characterization."
- [9] Mohamed M. Dessouky and Mohamed A. Elrashidy, "Feature Extraction of Alzheimer's Disease Images Using Different Optimization Algorithms"
- [10] "Improving Computer-Aided Detection Using Convolutional Neural Network and Random View Aggregation," Holger R. Roth, Le Lu, Jiamin Liu, Jianhua Yao, Ari Seff, Kevin Cherry, Lauren Kim, and Ronald M. Summers.



10.22214/IJRASET



45.98



IMPACT FACTOR:
7.129



IMPACT FACTOR:
7.429



INTERNATIONAL JOURNAL FOR RESEARCH

IN APPLIED SCIENCE & ENGINEERING TECHNOLOGY

Call : 08813907089  (24*7 Support on Whatsapp)