



# IJRASET

International Journal For Research in  
Applied Science and Engineering Technology



---

# INTERNATIONAL JOURNAL FOR RESEARCH

IN APPLIED SCIENCE & ENGINEERING TECHNOLOGY

---

**Volume: 9      Issue: XII      Month of publication: December 2021**

**DOI: <https://doi.org/10.22214/ijraset.2021.39683>**

**[www.ijraset.com](http://www.ijraset.com)**

**Call:  08813907089**

**E-mail ID: [ijraset@gmail.com](mailto:ijraset@gmail.com)**

# Role of HRCT in evaluation of Interstitial Lung Disease

Kajal Tyagi<sup>1</sup>, Shiv Kailash Yadav<sup>2</sup>, Anshu Kumar Singh<sup>3</sup>

<sup>1</sup>Lecturer, Department of Paramedical Sciences, Swami Vivekanand Subharti University, Meerut, U.P.

<sup>2</sup>Assistant Professor Department of Paramedical Sciences, Swami Vivekanand Subharti University, Meerut, U.P.

<sup>3</sup>Assistant Professor, Department of Paramedical Sciences, Swami Vivekanand Subharti University, Meerut, U.P.

**Abstract:** In this study, HRCT is the examination technique of choice as it is quickly accomplished, readily available and does not require ancillary studies using other imaging technologies in most cases. In this given study, A total of 40 patients were included in which 16 patients were found to be having ILDs, there were 10 male patients (62.5%) and 6 were female patients i.e., (37.5%) of total number of patients. Idiopathic pulmonary fibrosis were found in 3 (18.75%) patients, Usual interstitial pneumonia in 2 (12.5%) patients, Chronic Hypersensitive pneumonitis in 1 (6.25%) patient, Fibrotic hypersensitive pneumonitis in 4 (25%) patients and Pulmonary interstitial edema in 6 (37.5%). The maximum patients were found in pulmonary interstitial edema and minimum patients in Chronic Hypersensitive pneumonitis, the highest number of patients with interstitial lung disease were from the 60-80 Years age group category, which was 8 Out of 16 i.e. 50% of the total number of the patients and no patients were found from the age group 0-18 years age group and 80-100 years age group.

## I. INTRODUCTION

The lungs are the major organs of the respiratory system; these are cone-shaped, one lying on each side of the midline in thoracic cavity. The area between the lungs is the mediastinum. The right lung is divided into three lobes: superior, middle and inferior. On the other hand, the left lung is divided into two lobes- superior and inferior. The Interstitium, or interstitial space, provides a supporting framework for the delicate alveolar sacs. The interstitium comprises three freely communicating compartments: axial, parenchymal and peripheral. The axial space surrounds the primary bronchi and pulmonary artery as they enter the lung. (1) The parenchymal or alveolar interstitium provides delicate fibres to support the intra lobular air-exchanging portion of the lung. The space between the visceral pleura and the lung parenchyma is termed as peripheral interstitium and send strong supporting fibers to the parenchyma. The arrangements between the capillary and alveolar within the parenchymal interstitium are necessary to fully understand the radiographic appearance of interstitial and air-space patterns of lung disease. Normally, interstitium is not seen on radiographs.<sup>[2]</sup> Interstitial Lung Diseases (ILDs), sometimes called diffused parenchymal disease, describes a heterogeneous collection of distinctive lung disorders. In interstitial lung disease, inflammation or scarring (fibrosis) occurs in the interstitium of the lung. The interstitium of the lung refers to the microscopic area within the walls of the alveoli (air sacs) between the membrane of the air sac and the membrane of the surrounding blood vessels. Like the leaves on a tree, the alveoli arise from the tiniest bronchioles (airways). In interstitial lung disease, inflammation, scarring or fibrosis thickens the interstitium, making the lung thick and restricted from filling to their normal capacity and preventing oxygen from passing freely into the bloodstream.

## II. THE CAUSES OF ILD

The causes of interstitial lung disease (ILD) fall into four general categories. The first is autoimmune or connective tissue disease. Some autoimmune diseases that can cause ILD are:

- 1) Scleroderma (systemic sclerosis)
- 2) Rheumatoid arthritis
- 3) Polymyositis / Dermatomyositis
- 4) Large, medium or small vessel vasculitis
- 5) Inflammatory bowel disease.

The second category of cause of ILD is exposure to an agent that damages the lungs. For example, ILD can be caused by workplace exposure to inorganic dust — asbestos, silica or hard metal dust. Mould, bacteria or bird proteins are examples of organic dusts that can cause ILD. Smoking can cause ILD.

The third category is related to genetics. Multiple members of one family may develop ILD, and some of these cases have been tracked to a single set of genes. Some inherited diseases are known to cause ILD. Examples include Hermansky-Pudlak syndrome and Tuberous Sclerosis Complex.

The fourth category is called “idiopathic,” meaning the cause is unknown. Some examples of idiopathic ILD include:

- a) Idiopathic pulmonary fibrosis
- b) Idiopathic nonspecific interstitial pneumonia
- c) Acute interstitial pneumonia
- d) Sarcoidosis

The most common symptoms of ILD are:

- Shortness of breath, also known as dyspnoea, as well as cough and fatigue. Many people describe dyspnoea as a feeling of breathlessness.
- Cough due to ILD is typically a dry and hacking cough.
- Fatigue or low energy is very common in people with ILD.
- People with systemic autoimmune or connective tissue disease may have muscle or joint aches, rash and other non-respiratory symptoms.<sup>[3,4,5,6,]</sup>

### III. MATERIAL AND METHODS

It is a Prospective observational study, which is conducted on Philips Ingenuity Core 128 slice MDCT and Department of Radio diagnosis and Imaging, Chhatrapati Shivaji Subharti Hospital Meerut, U.P. Patients of all age groups scheduled for HRCT chest during data collection period.

Sample: 40 number of patients are included in this study.

#### A. Inclusion Criteria

Patients suspected of having interstitial lung disease suspected on chest radiograph. All the patients referred for HRCT chest with shortness of breath, suffering from dry cough are included. Patient with Auto-immune disease (rheumatology disease). Occupational and environmental exposure such as asbestos fibres .

#### B. Exclusion Criteria

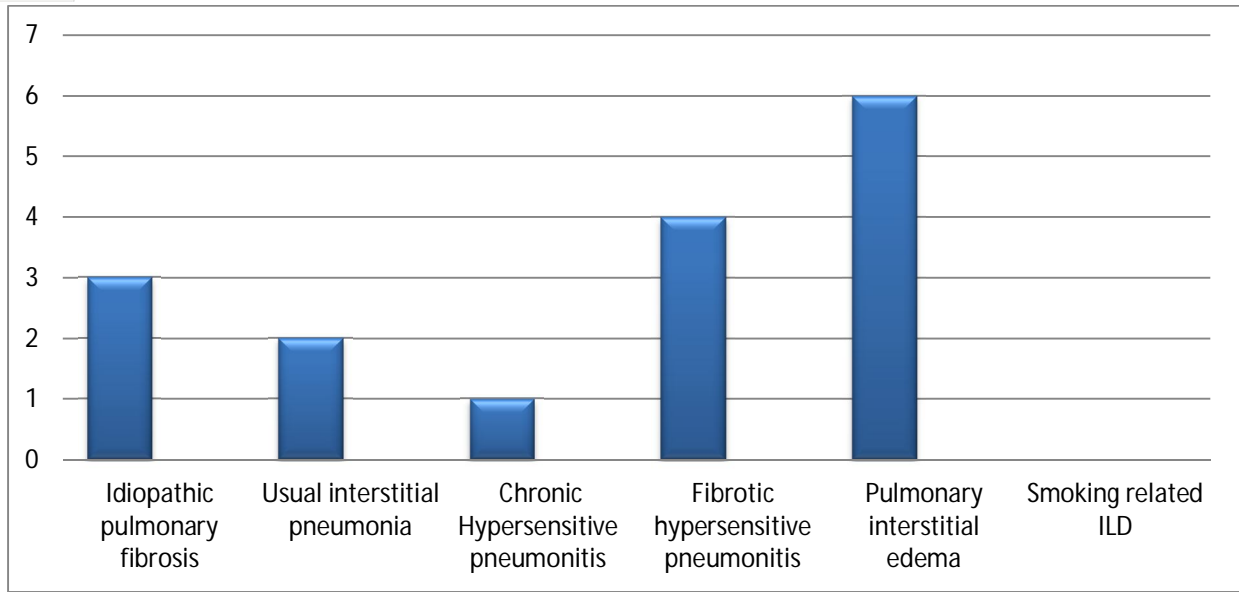
Pregnancy, Patients who didn't give consent, Uncooperative patient.

### IV. RESULT

There was no discrimination according to the gender of the patient in the study. Out of total 40 patients of HRCT chest, 23 patients were male which was 57.5% of total and 17 patients were female which was 42.5% of total patients. The ratio of the patients was 1.3:1. There was no discrimination of patients on the basis of age group. The patients were from of the age group of 8 to 90 years. The highest number of patients in the present study were found from the age group of 60-80 Years, i.e. 16 (40%) of the total number of the patients and it is observed that the lowest number of patients were from the age group of below 20 years i.e. 1(2.5%). In 40 patients, 16 patients were found having ILDs, Idiopathic pulmonary fibrosis were found in 3 (18.75%) patients, Usual interstitial pneumonia in 2 (12.5%) patients, Chronic Hypersensitive pneumonitis in 1 (6.25%) patient , Fibrotic hypersensitive pneumonitis in 4 (25%) patients and Pulmonary interstitial Edema in 6 (37.5%). The maximum patients were found in pulmonary interstitial Edema and minimum patients in Chronic Hypersensitive pneumonitis.

Table no. 1 Distribution of patients according to ILDs

Interstitial lung disease	Frequency	Percentage
Idiopathic pulmonary fibrosis	3	18.75
Usual interstitial pneumonia	2	12.5
Chronic Hypersensitive pneumonitis	1	6.25
Fibrotic hypersensitive pneumonitis	4	25
Pulmonary interstitial oedema	6	37.5
Smoking related ILD	00	00



### V. CONCLUSION

The two imaging modalities that are used almost routinely in the assessment of patients with interstitial lung disease (ILD) are chest radiography and high resolution computed tomography (HRCT). It is concluded that HRCT can depict the normal and abnormal interstitium with anatomic detail and has become the imaging modality of choice with suspected ILD.

### VI. ACKNOWLEDGEMENT

I am very thankful to Swami Vivekanand Subharti University, Meerut for providing us a facility to perform this work. I am also very thankful to my Co – Authors Shiv Kailash Yadav and Anshu Kumar Singh for their help and guidance throughout the entire work.

### VII. CONFLICT OF INTEREST

I declare that there is no conflict of interest.

### VIII. AUTHOR’S CONTRIBUTIONS

All authors listed have made a substantial, direct, intellectual contribution to the work and approved it for publication.

### Funding

None

### REFERENCES

- [1] Jain A. K. (3rd edition)-Anatomy and Physiology for nursing 2013.
- [2] Marchiori Dennis M. - Interstitium Clinical imaging (Third Edition), 2014.
- [3] Altraja Alan, Department of pulmonary medicine, University of Tartu-interstitial lung diseases(ILD) or diffuse parenchymal lung disease (DPLD) Idiopathic interstitial pneumonia (IIP) 2017.
- [4] Antoine Marrha et al., Interstitial lung disease, <http://creativecommons.org/licenses/by/2.0> published on 2020
- [5] Churg Andrew and Muthers Nestor L. -Atlas of interstitial lung disease pathology, (2015).
- [6] Schwarz marwin I. et al., Atlas of Interstitial Lung Disease , fifth edition (2011).



10.22214/IJRASET



45.98



IMPACT FACTOR:  
7.129



IMPACT FACTOR:  
7.429



# INTERNATIONAL JOURNAL FOR RESEARCH

IN APPLIED SCIENCE & ENGINEERING TECHNOLOGY

Call : 08813907089  (24\*7 Support on Whatsapp)