



IJRASET

International Journal For Research in
Applied Science and Engineering Technology



INTERNATIONAL JOURNAL FOR RESEARCH

IN APPLIED SCIENCE & ENGINEERING TECHNOLOGY

Volume: 6 Issue: IV Month of publication: April 2018

DOI: <http://doi.org/10.22214/ijraset.2018.4475>

www.ijraset.com

Call:  08813907089

E-mail ID: ijraset@gmail.com

Detection of Diabetic Retinopathy: A Survey

Nisha A. Panchal¹, Dr. Darshak G. Thakore², Dr. Tanmay D. Pawar³

^{1, 2, 3}Computer Engg. Dept., ³ Electronics Dept., BVM Engineering College

Abstract: Diabetic Retinopathy (DR) is a severe condition for the diabetic patient in their eye ailment. This issue can be detected from the retinal fundus image. Microaneurysms (MAs), Hemorrhages (HMs) and Exudates (EXs) are three features of non-proliferative diabetic retinopathy. Microaneurysms are the earlier stage of DR. There are many methods or techniques proposed till date for detection of the disease in the eye from the retinal fundus image. This paper aims to survey some techniques to detect blood vessels, optic disc exudates (EXs), microaneurysms (MAs) and Hemorrhages (HMs) and then classified using different classifier.

Keywords: Microaneurysms, Hemorrhages, Exudates, Image processing, Morphological operation, SVM.

I. INTRODUCTION

Diabetic retinopathy (DR) is a disease that occurs due to diabetes. The diabetes damages the retina of the patient's eye hence disease is called diabetic retinopathy. This disease can change into permanent blindness [9]. DR can be classified into several levels on basis of threat level to the patient. The first stage is Non-Proliferative Diabetic Retinopathy (NPDR), the threat levels are mild, moderate and severe while the second stage is Proliferative Diabetic Retinopathy (PDR) which causes complete blindness [5]. The early stage of DR is Microaneurysms (MAs) which are formed due to swelling of small blood vessels in the retina. Hemorrhages (HMs), hard exudates (EXs) and soft exudates (EXs) are the next signs of the Non-Proliferative Diabetic Retinopathy [6]. Fig. 2 shows the classification diabetic retinopathy.

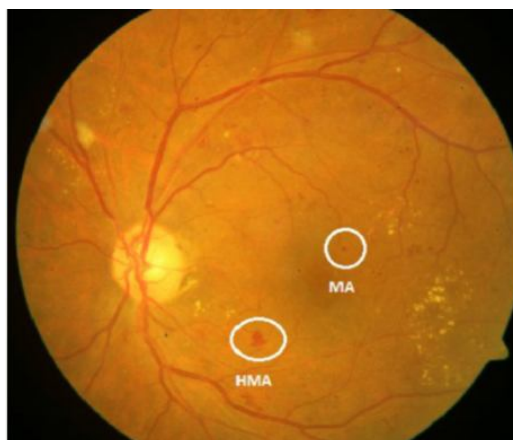


Fig.1 Microaneurysms and Hemorrhage [1]

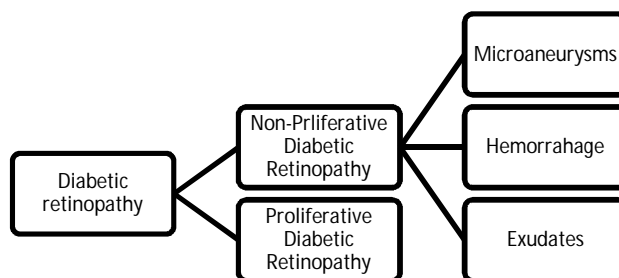


Fig. 2 Classification Diabetic retinopathy

MAs and HMs are the foremost symptoms of the diabetic retinopathy [1]. MAs are minute blood-filled bulges in the artery walls [20] while HMs occur due to bleeding in light-sensitive tissue on the back wall of an eye [19]. HMs appear as red spot but larger than MAs. Figure 1 shows both of the symptoms. EXs are nothing but some fluid, oily by nature [7] and appearing as yellowish regions [6]. This all symptoms are detectable using the fundus image of the retina. When above all three symptoms occur together it a severe level of non-proliferative diabetic retinopathy. MAs are pre-symptoms of the diabetic retinopathy. So detecting MAs is very helpful to the patient of the diabetic retinopathy.

In this survey, several papers were studied. Most of the work was based on detecting MAs, HMs, and EXs. Also, the distribution of this symptom shows the threat level to the patient eyesight loss. Saranya et al. [1] have applied two approaches, that are semi-automated Hessian-based candidate selection (SHCS) algorithm and Automated Hessian-based candidate selection (AHCS) algorithm. Niladri et al. [2] subsequently applied pre-processing techniques, detection and removal techniques of exudate, blood vessels, and optic disc, and then objects which are smaller or equal to 10 pixels detected as MAs. Shan et al. [3] developed new adaptive template matching approach using a dynamic multi-parameter template with the restriction of a sum of errors and correlation coefficients (DMPT-SC). Syan et al. [4] used segmentation, canny edges, and then entropy thresholding followed by some pre-processing for removing noise in the retinal image. Shirbahadurkar et al. [5] used morphological operation and Gabor filter for feature extraction and then classification using Support vector machine and feed-forward neural network. Sharath et al. [6] detect optic disc, blood vessels and white/yellow lesions using different image processing methods and for detection of red lesions, they removed all detected features like an optic disc, blood vessels and white/yellow lesion from the pre-processed. Dilip et al. [7] applied pre-processing, extract features like blood vessels area, optic disc area, EXs area, HMs area, MAs area, Shannon entropy for classification and quantitative analysis. MAs and EXs both are extracted using Selective Binary and Gaussian Filtering regularized Level Set (SBGFRLS) on pre-processed fundus images and matched filter with the first-order derivative of Gaussian (MF-FDOG) is used to detect blood vessels [8]. Pre-processing techniques followed by extraction of features like blood vessels, MAs, optic disc, EXs and then applied SVM classification [10]. Enrique et al. [11] applied same flow chart as [10] but used different methods for extraction and used two classifiers SVM and decision tree. After applying pre-processing technique feature extraction, feature selection using Haar wavelets and principal component analysis is done and then applied classification techniques like OneR and BPNN [12]. Manjula et al. [13] applied pre-processing techniques, extract blood vessels, detect candidate region, and Eigenvalue analysis for MAs detection.

Following paper organized accordingly. In the next section, the methodology used for detection of diabetic retinopathy are illustrated. A survey on pre-processing, features of diabetic retinopathy and classification. Section 3 is about a dataset. Final thoughts summarized in last section conclusion.

II. METHODOLOGY

There are various methods used in process of detection of DR. Divide the process into three steps pre-processing, the feature of DR detection and classification.

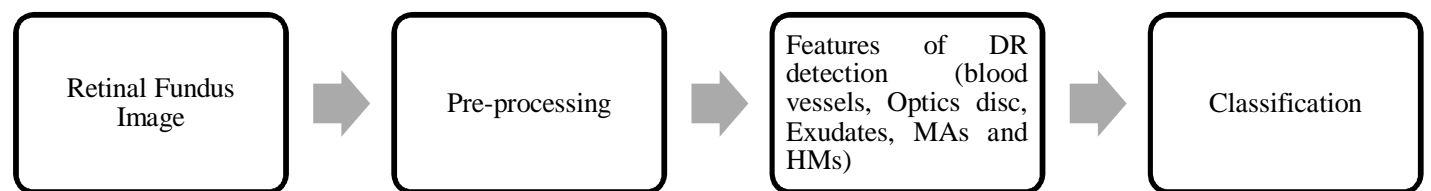


Fig. 3: flow chart of Diabetic retinopathy [10]

A. Pre-processing

Pre-processing is an important step in process of detecting DR. Most of the researchers convert retinal fundus image into green channel [1-3], [5-8], [10-14] as a contrast of MAs and HMs are high in this channel. Contrast limited adaptive histogram equalization (CLAHE) is applied to enhance the image and then median filter to remove noise [4, 6, 7 and 10]. 2D wavelet transform and median is also applied as pre-processing in [4]. Resize the image to reduce processing time [4, 6, 7 and 10]. Gabor filter is used to enhance blood vessels [5].

B. The Feature of DR detection

- 1) *Blood Vessels detection:* MAs, HMs, and EXs are the main reason for blood vessel damage. So the blood vessels detection is an important factor for detection of DR. Blood vessels area in the normal retinal image is approximately 37230.57 [7] but DR image has less than this area because of contraction. The Morphological operation followed by thresholding is applied to detect [2, 12] blood vessels. Retinal fundus image is converted into HSV color image then applied bi-cubic interpolation, gamma correction, median filter, and thresholding technique to segment blood vessels [6]. Match filter and first-order derivation of Gaussian matched filter technique are applied in [8]. Fuzzy C-Means clustering and morphological operations are used to detect blood vessels [10]. The Retinal fundus image is converted into a CMY color image after that isolate Magenta channel [11]. On that channel morphological operations and thresholding is applied.
- 2) *Optic disc detection:* The Optic disc is bright yellow portion and approximately circular in shape [6]. To detect EXs, we need to detect a portion of the optic disc in retinal fundus image because Optic disc and EXs both have same intensity [7-8]. Optic disc mark was created using brightest pixels in an image and its coordinates are a center of the marks [2, 10]. Three facts are used to detect optic disc [6]. The first fact is image acquisition and prior information such as a left or right eye. The second fact is a representation of Optic disk as a bright yellow portion. The Third fact is optic disc is circular in shape. The Morphological operation followed by watershed segmentation is used to segment optic disc in [8]. Create a binary image of Difference between a green channel and cyan channel of retinal fundus image after that dilation and Hough transform are applied to create optic disc mark [11].
- 3) *EXs Detection:* Exudates are bright yellow objects in retinal fundus image which have less than 100 pixels in fundus image [2]. Maximum entropy double thresholding technique is applied to define both high and low bright features without affecting the background [4]. Finally, to detect exudates remove all the objects which are greater than 3000 pixels. A brightness of fundus image is changed using non-linear curve with HSV (Hue saturation value) space [6] and then gamma correction applied on a red and green component to enhance the EXs. Finally, EXs candidates were detected using histogram analysis [6] and remove false EXs using multi-channel histogram analysis. To segment EXs from pre-processed image SBFRL (Selective binary and Gaussian filtering regularized level set) is applied [8]. Harini et al.[10] used to add results of two operations for detecting EXs. The First operation used top-hat transformation and illumination correction for background exclusion and other operation uses blood vessels removal, segmentation and logical '&' operation. Convert retinal fundus image into a CMY color model and then extract magenta component [11] to detect EXs. On magenta component applied thresholding base on a standard derivation of a magenta component to convert an image into binary image and then remove optic disc portion from a binary image. Finally to extract EXs apply morphological operation on the binary image. Morphological operation and segmentation techniques [12] are used to detect EXs.
- 4) *MAs and HMs Detection:* Microaneurysms and Hemorrhages are first DR symptoms. If we detect the earlier stage then we can reduce the blindness causes from DR. Two methods are used for detecting MAs and HMs [1]. The first method is Semi-automated DR detection using Eigenvalue of Hessian matrix Analysis. The second method is automatic DR detection using Eigenvalue of hessian matrix analysis, image processing techniques, and SVM classifier. DMPT-SC (Dynamic template scheme) is used to extract MAs [3]. They extract shape, pixels, algebra, and other features for template matching process. And also they used DCS-AWS (Adaptive weighted scoring algorithm with distribution character based scoring scheme) to achieve high sensitivity [3]. Canny edge detection is applied to a pre-processed image and then applied Hole Fill MATLAB technique [4]. Finally to extract MAs they subtract Hole Filled image and canny edge detected image. All features like blood vessels, optic disc and exudates are detected using different image processing techniques [2, 6, 8 and 10]. And then detection of MAs take a place using different methods. Objects which are equal or smaller than 10 pixels detected as a MAs [2]. Matched filter and thresholding techniques were used to detect MAs and HMs [6]. INPAINTING technique is used to remove all the features from the pre-processed image and then extended minima transform is used to detect MAs [8]. Pre-processing techniques were used to enhance the image and then remove blood vessels from a pre-processed image, and then they created feature vector using gray level co-occurrence matrix, wavelet features and statistical features like area and shape. And used two classifier SVM and LMNN to detect MAs [5]. Methods like green channel, histogram equalization, and morphological operations are used to detect MAs and HMs in [7]. Blood vessels are removed using average retina color and then disc based dilation is applied to highlight MAs [11]. Edge detection and Hole Filling technique are applied to the dilated image. And subsequently, process these images to get possible MAs. Preprocessing techniques were brightness correction, gamma correction, green plane extraction, histogram equalization and thresholding is applied [13]. Subsequently, extract and remove blood vessels and Eigenvalue analysis to detect candidate region of MAs.

C. Classification

Different tools and techniques are developed for the classification using some samples. The aim of this topic is to differentiate the planes from where the testing samples are to be classified. The important aspect on which the accuracy of the system depends on the classifier. Whatever the feature extraction is done to create a redundant and efficient data that has to be submitted to the classifier where the classifier is given some data for training purpose. Ten fundus images were finally given to the Support Vector Machine (S.V.M.) for training which consisted of positive and negative samples with specific labeling [1]. In addition, the principal component analysis was also applied to the trained classifier.

While similarly in [5] feature vector formed by the system is given to the S.V.M. They also used multi-layered feed forward network which is a Levenberg-Marquardt neural network algorithm to classify in MA's and Non-MA's. Similarly, S.V.M. classifier is used to create positive and negative planes and then test the data using trained S.V.M. classifier [10]. S.V.M. and decision tree were used but in two-phase DRNP detection and DRNP grade classification [11]. Two classifiers are used OneR classifier and BPNNs [12].

- 1) **SVM:** S.V.M. is a supervised training algorithm. Which used some training data set for the classification according to the number of class, and the dimension of the classifier can be increased. The classifier works in a way that the most relevant samples from the subplanes are used for creating the planes for the classification. SVM as a two-class classifier is also called linear classifier where only two dimensions or two classes are possible in which data samples are to be classified [21]. The SVM classifier takes the input of feature vector which is the result of the feature extraction techniques. The result formed after the extraction of the feature are stored in feature set form that can be given to the SVM classifier for the training. These Samples are also an aspect of the accuracy or the efficiency of the SVM classifier for the classification. SVM can also be used as the multi-class SVM where many "One-to-one SVM" classifier are combined to get a classifier for the required number of the class [21]. This is a way of increasing the dimension so that in our aspect of DR detection wherein [11] different grade of the disease are classified.
- 2) **OneR:** The OneR stands for one rule. This classification technique is simple yet accurate to classify. It creates set of rules for each predictor and picks the rule with a least total error [25]. For this purpose, it generates frequency table against the target. This generated rule is humanly understandable. To generate one rule training data, attributes, and classes are taken as input and generate a set of rules for each attribute with the highest accuracy and minimum error.
- 3) **LMNNs:** Levenberg-Marquardt Neural Network is a multilayer feed-forward artificial neural network based on a mathematical model known as a Levenberg-Marquardt algorithm [22]. This mathematical model is used to update the weights in the neural network. The algorithm is combined while training the algorithm shifts to the steepest descent algorithm [5].
- 4) **BPNNs:** Back Propagation Neural network is a multi-layered feed forward neural network. The training goes by updating the internal weight of the nodes for the precision. The training data set are taken for the training of the neural network. The training dataset has defined output which is given to the neural network. The difference between the actual and required output called an error is used to update the nodes in backpropagation in a way where the updating of the nodes travel from the output nodes to the internal nodes and the weights are the adjusted approximately and then subsequently the new output is achieved and the same process is repeated until the error is minimum or null [23].
- 5) **Decision tree:** This a very basic yet very useful in classification and regression hence also called a CART (classification and regression tree). In this, a tree is constructed in a way where a class attribute is taken as a leaf node and other attributes are taken as an internal node [24]. The trees are constructed based on the probability of DR attributes denoting disease is taken into account on basis of which the tree is constructed. This constructed tree can also be viewed in the form of statements like P implies Q. As decision tree is based on a probability of the attribute so a selection of the attribute is important and also in some case number of an attribute is also important. On this both factor, the accuracy and the efficiency of this classifier are dependent. The different attribute from the training dataset's fundus image is to be extracted by feature extraction techniques which have to be given for the construction of the decision tree and then similar attributes have to be extracted from the testing fundus image and given to the classifier were based on the constructed tree classification is done.

III. DATA-SET

The below Table [26] shows the dataset used in the surveyed paper. Each of the dataset used is used only for the research purpose only. Some of the authors obtained their dataset using their local hospital or any other sources.

TABLE-1
Database Of Fundus Images

Sr_No	Name	Resolution	No. of image	Image acquisition
1	DRIVE[14]	768×584	Testing-20, Training -20	3-CCD Camera with 45-fold view
2	DIARETB0[15]	1500×1152	130 images, Normal-20, DR-110	50-fold view
3	DIARETB1[16]	1500×1150	89 images, Normal-5, DR-84	50-fold view
4	Messidor[17]	1440×960, 2240×1488, and 2304× 1536	1200 images	3-CCD Camera with 45-fold view
5	e-ophtha-MA[18]	2048 × 1360	148 images with microaneurysms or small hemorrhages and 233 images with no lesion.	OPHDIAT© Tele-medical network
6	e-ophtha-EX[18]	2048 × 1360	47 images with exudates and 35 images with no lesion.	OPHDIAT© Tele-medical network

IV. CONCLUSION

In all surveyed paper the researchers had used different standalone methods to detect the DR in the fundus image. Few of the surveyed paper has given complete specificity and accuracy, also in the surveyed papers processing time is not taken into the account. So to achieve complete accuracy some hybrid approach can be taken in further work. Also relevant to the feature extraction specific classification techniques to be picked so we can achieve good accuracy and specificity. Also, the process time can be decreased in future.

REFERENCES

- [1] S.Saranya Rubinia and Dr.A.Kunthavaib, “Diabetic Retinopathy Detection Based on Eigenvalues of the Hessian Matrix”, *Procedia Computer Science*: vol. 47, pp. 311 – 318,2015.
- [2] Niladri Sekhar Datta, Himadri Sekhar Dutta, Mallika De, Saurajeet Mondal, “An Effective Approach: Image Quality Enhancement for Microaneurysms Detection of Non-Dilated Retinal Fundus Image”, *Procedia Technology*: vol. 10, pp.731 – 737,2013
- [3] Shan Ding, and Wenyi Ma, "An Accurate Approach for Microaneurysm Detection in Digital Fundus Images", proceeding of the IEEE International Conference on Pattern Recognition (ICPR), pp. 1847-1851, Stockholm, Sweden, Aug. 2014
- [4] Syna Sreng, Noppadol Maneerat, Kazuhiko Hamamoto, “Automated Microaneurysms Detection in Fundus Images Using Image Segmentation”, proceeding of IEEE International Conference on Digital Arts, Media and Technology(ICDAMT), Chiang Mai, Thailand, March 2017
- [5] S.D. Shirbahadurkar, Vijay M. Mane, and D.V. Jadhav, “Early Stage Detection of Diabetic Retinopathy Using an Optimal Feature Set”, *Proceedings of Third International Symposium on Signal Processing and Intelligent Recognition Systems (SIRS-2017)*, Manipal, India, September 13-16, 2017.
- [6] Sharath Kumar P Na, Deepak R U, Anuja Sathar, Sahasranamam V, Rajesh Kumar R, “Automated Detection System for Diabetic Retinopathy Using Two Field Fundus Photography”, *Procedia Computer Science*: vol. 93,pp. 486 – 494, 2016.
- [7] Dilip Singh Sisodia, Shruti Nair, and Pooja Shobragade, “Diabetic Retinal Fundus Images: Preprocessing and Feature Extraction For Early Detection of Diabetic Retinopathy”, *Biomedical & pharmacology journal*: vol. 10(2), pp. 615-626, 2017.
- [8] Manoj Kumar, Manikandan, Malaya Kumar Nath, “Detection of Microaneurysms and Exudates from Color Fundus Images by using SBGFRLS Algorithm”, *Proceeding of International Conference on Informatics and Analytics (ICIA)*, ACM, New York, NY, USA, Aug. 2016.
- [9] https://en.wikipedia.org/wiki/Diabetic_retinopathy
- [10] Harini R and Sheela N, “Feature Extraction and Classification of Retinal Images for Automated Detection of Diabetic Retinopathy”, proceeding of IEEE International Conference on Cognitive Computing and Information Processing (CCIP), Mysore, India, Aug. 2016.
- [11] Enrique V. Carrera, Andres Gonzalez and Ricardo Carrera, “Automated detection of diabetic retinopathy using SVM”, proceeding of IEEE International Conference on Electronics, Electrical Engineering and Computing (INTERCON), Cusco, Peru, Aug. 2017.
- [12] Deepthi k Prasad, Vibha L ,and Venugopal K R, “Early Detection of Diabetic Retinopathy from Digital Fundus Images”, proceeding of IEEE International Conference on Intelligent Computational System (RAICS), Trivandrum, India, Dec. 2015.



- [13] R. Manjula Sri and V. Rajesh, "Early detection of diabetic retinopathy from retinal fundus images using Eigen value analysis", proceeding of International Conference on Control, Instrumentation, Communication and Computational Technologies (ICCICCT), Kumaracoil, India, Dec. 2015.
- [14] <https://www.isi.uu.nl/Research/Databases/DRIVE/>
- [15] <http://www.it.lut.fi/project/imageret/diaretdb0/index.html>
- [16] <http://www.it.lut.fi/project/imageret/diaretdb1/>
- [17] <http://www.adcis.net/en/Download-Third-Party/Messidor.htmlindexen>.
- [18] <http://www.adcis.net/en/Download-Third-Party/E-Ophtha.html>.
- [19] https://en.wikipedia.org/wiki/Retinal_haemorrhage
- [20] http://www.retinaandmacula.com/retina/retinal_microaneurysm_bonita_springs.htm
- [21] https://en.wikipedia.org/wiki/Support_vector_machine
- [22] https://en.wikipedia.org/wiki/Levenberg%E2%80%93Marquardt_algorithm
- [23] https://en.wikipedia.org/wiki/Artificial_neural_network
- [24] https://en.wikipedia.org/wiki/Decision_tree
- [25] Classification – basic method, Dr. Saed Sayed, PDF file, University of Toronto, 2010, http://chem-eng.utoronto.ca/~datamining/Presentations/Basic_Methods.pdf
- [26] Javeria Amin, Muhammad Sharif, and Mussarat Yasmin, "A Review on Recent Developments for Detection of Diabetic Retinopathy", Hindawi Publishing Corporation Scientifica: vol. 2016.



10.22214/IJRASET



45.98



IMPACT FACTOR:
7.129



IMPACT FACTOR:
7.429



INTERNATIONAL JOURNAL FOR RESEARCH

IN APPLIED SCIENCE & ENGINEERING TECHNOLOGY

Call : 08813907089  (24*7 Support on Whatsapp)