



iJRASET

International Journal For Research in
Applied Science and Engineering Technology



INTERNATIONAL JOURNAL FOR RESEARCH

IN APPLIED SCIENCE & ENGINEERING TECHNOLOGY

Volume: 6 Issue: IV Month of publication: April 2018

DOI: <http://doi.org/10.22214/ijraset.2018.4701>

www.ijraset.com

Call: ☎ 08813907089

E-mail ID: ijraset@gmail.com

Glucoma Detection using Image Processing Techniques

Rathva Rupal¹, Prof Kirti Kumar J. Sharma², Dr Maulika S. Patel³

¹ PG Scholar Birla VishvaKarma Mahavidyalaya Engineering College, Vallabh Vidhyanagar, Gujarat, India

² Assistant Professor Birla Vishvakarma Mahavidyalaya Engineering College, Vallabh Vidhyanagar, Gujarat, India

³ Professor, G H Patel College of Engineering and Technology, Vallabh Vidhyanagar, Gujarat, India

Abstract: *Glaucoma is a most noticeable cause of vision loss in human subjects. It disturbs the optic nerve as a significance of which loss of ganglia cells in retina of the eye takes place and this damage ultimately causes to sight loss. The primary reason of glaucoma is improved intraocular pressure which disperses the optic nerve. In this Paper glaucoma is classify by extract two features with retinal funds images (i) Cup to disc ratio . The techniques used for the automatic detection of glaucoma are applying the RGB images of Retinal funds images. The techniques mention in the current report is based on the HSV retinal images and the histogram analysis and Expectation Maximization Algorithm are used for detection of region of interest.*

Keywords: *CDR (Cup to Disc Ratio), Neuroretinal Rim (NRR), Morphological Methods, Retinal Fundus Images.*

I. INTRODUCTION

Glaucoma is a most often cause of vision loss in human subjects. There is no a perfect cure for glaucoma. It disturbs the optic nerve as a significance of which loss of ganglia cells in retina of the eye takes place and this damage at last causes to sight loss.

It is often associated with the increased in the intraocular pressure (IOP) of the fluid in eye, and it has been nicknamed as the “Silent Thief of Sight” [1]. It comes along with an enduring destruction of optic nerve head (ONH) cause by an enhance in intraocular pressure inside eye [1]. Thus, timely detection of glaucoma is desirable to avoid Sight loss. Manual check of retinal fundus images required more time and precision rest on the proficiency of the experts. Unstructured investigation of retinal fundus images is appropriate an important tool these days. In Normal eyes, there is normal balance between the fluids that is produced in the eye and the second that leaves the eye through eye’s drainage system. This balance of fluids Keeps Inter Ocular pressure (IOP) surrounded by the eye irregular but in Glaucoma, the balance of fluid created surrounded by the eye is not maintain properly which in causes and increase in IOP, ensuing in the damage of optic nerve. [1] As for normal disc the CDR is consider individual less than 0.5 but in case of glaucoma, it is greater than 0.5 [2] as the cup range amplify it also affect the Neuroretinal Rim (NRR) [2]. We have detected the cup-to-disc ratio (CDR) to identify the Disease at the early stage and used classification to classify the severity of the disease [6].

II. SYMPTOMS OF GLAUCOMA

The leading sign of glaucoma is often the loss of side vision, which may not notice as the disease extends. This is why glaucoma is often called the “sneak thief of vision”. In the case of server level in intraocular pressure, unexpected eye pain, blurred vision, or the exterior of halos around lights may occur. [7]

- 1) Vision loss.
- 2) Redness in the eye.
- 3) Eye that looks hazy
- 4) Vomiting or Sickness.
- 5) Unexpected loss of sight.
- 6) Narrowing of vision

A. Types Of Glaucoma

There are two main kinds of glaucoma:

- 1) *Open—angle glaucoma:* It is most frequent type which type may also called as “wide- angle glaucoma”.
 - a) Glaucoma is quite insensible.
 - b) Loss of sight by the disorder like glaucoma is irreversible by available treatments and also from surgery.

- c) AS the disorder affects the vision peripheral
- 2) *Angle-Closure Glaucoma*: It also called as “acute or chronic angle-closure” or “narrow-angle glaucoma”.
 - a) Vomiting
 - b) Unclear or. cloudy sight
 - c) The presence of rainbow-colored circles around bright lights
 - d) Various eye and head aching problem
 - e) Unexpected loss of sight

III. DATASET

RIMONE (An Open Retinal Image Database for Optic Nerve Evaluation) [9] is the fundus image dataset based on the ONH centred images. The experimental evaluation demonstrated that the classification accuracy of normal and glaucoma images. The original JPEG compressed color images in PNG format. The dataset has 62 normal and 48 glaucoma images.

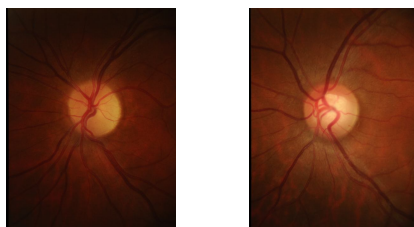


Fig 1 Retinal Fundus Images [9]

IV. METHODOLOGY

In this Work, two Parameter are required to be removed by Mean Threshold Morphological Method in organize to evaluate CDR and to discover NRR ratio in ISNT quadrants. For CDR evolution, optic disc and cup is required and to find NRR ratio in ISNT quadrants.

A. Pre-Processing

In Color retinal images, Optic disc appear to be the brightness part having pink or light orange color and is considered to be Region on Interest. It incorporates the elimination of unwanted signals or useless data from the rough image. It also includes uplifting the image quality, filtering and relic elimination. The ROI is extracted from the fundus image with the help of colour channel separation in Matlab software.

B. Extraction of Optic Disc And Optic Cup

The original coloured fundus image was converted to HSV plane. After analyze a number of images, it was concluded that optic disc has a better contrast in V plane extract from HSV image For extraction of optic cup, the green plane is extracted from original image which provides better contrast for optic cup. Evaluation of CDR is one of the key Element, which is calculated by the extraction of optic disc and cup. The V plane from HSV image is extracted from the original retinal image This area of the OC and OD are measured with the help of contrast information of the fundus picture using superpixel classification technique between the OD and OC For this morphological operation such as dilation and erosion is performing as definite in equation (1) and (2). In dilation cause objects to produce in size by calculation pixels to the boundaries of the object in the input images.

The dilation of A and B is Defined by:

$$A \oplus B = \bigcup_{b \in B} A_b \quad \text{--- (1)}$$

The erosion of A and B is Defined by:

$$A \ominus B = \bigcap_{b \in B} A_{-b} \quad \text{--- (2)}$$

Here A is binary image

B is structuring elements

For edge detection “Canny filter” is applied on resultant binary images of both optic disc and cup.

$CDR = \text{Area of the Cup} / \text{Area of the Disc}$

The cup-disc ratio increases over a threshold value, we consider that the patient is suffering from glaucoma.

C. Extraction of Neuroretinal Rim

Extracted the NRR area for the detection of glaucoma [8]. If the ratio of the blood vessel area in the nasal and temporal side is more than the ratio of blood vessel area in the superior and inferior quadrant, then it is Glaucomatous. The optic disc and the cup were extracted separately. NRR was extracted by just applying an AND operation to the binary images of both disc and cup. A mask image of a particular size was applied on extracted NRR image in order to measure the ratio of areas covered by NRR in the ISNT quadrants.

D. CDR (Cup-to-Disc Ratio)

The cup-to-disc ratio is extensively observed as one of the substantial indication of the risk factor for the identification of glaucoma, which is one of the major causes of blindness universally. The precise dimension of the CDR is imperative to obtain an accurate assessment of the presence of glaucoma in a patient, composed with other clinical tests such as intraocular pressure and visual field acuity.

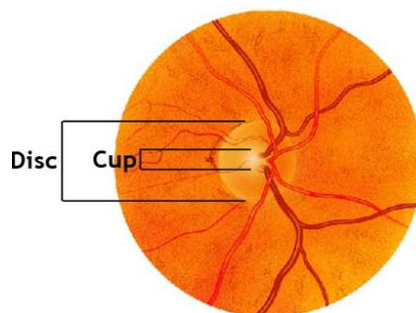


Fig.2. Retinal fundus image with cup and disc notation [4]

As shown in the figure 2, we can see in the retinal fundus image, in the whole perimetry of eye, the optic cup is located inside the optic disc. For the glaucoma detection, the optic disc is first detected and then in that the located optic cup is detected. Here the detection of optic cup is more challenging task than the detection of optic disc. After that, the area of the individual optic disc and optic cup is calculated and then the Cup-to-Disc Ratio (CDR) is calculated based on the obtained values [12].

E. Classification

It is a technique for image analysis used for estimating statistical parameters corresponding to the gray level intensity values of the pixels. It involves labeling of a group of pixels depending upon the grey level values and other statistical parameters [4]. After the preprocessing and the feature extraction the next requisite step that is followed is classifying the subjects or the images as Glaucoma or normal. Glaucoma classifiers employ input vectors that have contrasting features like Cup-To-Disc Ratio.

V. LITERATURE SURVEY

Kavitha.[5] implemented the optic Disc Segmentation using the Direct analysis of original image for threshold value, Color Component Analysis for optic disc, ROI based segmentation and Optic Cup Segmentation using the Method of component analysis for the optic cup.

After the above methods, the Cup-to-disc ratio (CDR) is calculated. Here the analysis of the value of cup to disc ratio was carried out for examining the glaucoma. The Cup to Disc Ratio was calculated by the ratio of the area covered by the optic cup region and area covered by the optic disc region. If here the value of cup to disc ratio was more than 0.3 then it was indicating that the eye was having the risk of glaucoma otherwise no risk of it. The main benefit of this method was its capability to associate the gaps in the located image features.

The execution of the different methods was evaluated by contiguity of the computed cup to disc ratio to the manual calculated clinical cup to disc ratio. They were suggested that the combined results of extracted region of interest with the component analysis method were giving more accurate computation for the cup to disc ratio. The above method was tested nearly on the about 300 images and classified the glaucoma correctly.

LekshmiShy[7] focused on early detection of disease. A method based on high pass filtering and morphological operation is introduced in the proposed method for vessel segmentation which in turn helps glaucoma detection. Here glaucoma is detected by means of ISNT ratio. The analysis is performed on Glaucomatous and normal eye. Ten images of each are collected from the database and ISNT ratio is calculated on each. The concept here is to calculate the area of the blood vessels in all the quadrants which makes the system simpler and accurate detection of glaucoma.

A. In This Paper, Follow the Steps as Follows

- 1) Input image is selected from the database.
- 2) Contrast enhancement and vessel enhancement are performed on the green plane of the input image.
- 3) First a low pass filtering is done on the enhanced image using a median filter and then high pass filtered image is generated. Negative of the enhanced image is taken.
- 4) To that reconstruction is performed on the negative of the image.
- 5) The region common to the high pass filtered image and tophat reconstructed image is taken as the vessel region.
- 6) Mask is generated to filter one quadrant.

Chetan Tulasigeri[8] implemented Glaucoma is detected whenever there is change in the retinal inside eye structure, which is the change in the characteristics of the cup and disc area of nerve head and it is also called as undying loss of the vision capacity. Advance thresholding algorithm is used for cup and disc segmentation. This algorithm is based on spatial variations in the illumination. The system model segmentation is highly perfect and more efficient for the computation. This disease is caused by the peri papillary atrophy region with the high pressure of the nerve head. This proposed algorithm is designed and implemented with efficient architecture and hardware implementation for the purpose of real time operation is carried out.

A color fundus image is assigning the RGB and NTSC format, according to these format first, I am assigning the cup and disc to a particular channel, after the assigning to the channel. This can be converted retinal fundus image into the gray scale image for the purpose of the segmentation. The conversion image is mainly consist of the high gray scale conversion and it is mainly useful for the segmenting the optic disc and cup area.

B. The Steps Suggested by the Authors for Detection Were as Follows

- 1) The input retinal color image is captured by the fundus CFI camera.
- 2) The input image is converted into gray scale image.
- 3) Applying morphological operation such as dilation and erosion for the purpose of removing blood vessels.
- 4) Converting image into the binary by using the gray threshold value.
- 5) Apply median filter techniques for image blurring and removing of noise.
- 6) Select the threshold from the histogram.
- 7) The segmentation is carried by select threshold value
- 8) Using watershed segmentation process for masking the cup area. According to masking process, calculated the disc area by counting the pixels present at the disc area.
- 9) CDR calculation is helps to identify the disease.

Agaiwal[9] used the adaptive threshold based method because it was unrelated with the image quality and also invariant to noise, for the extraction of the optic disc and optic cup and then calculate the cup to disc ratio which is used for the detection of the glaucoma. In this method, they were used the statistical parameters like mean and standard deviation explored from the histogram analysis of the retinal fundus image for the tracking of the threshold value of the different regions available inside the image. Then the optic disc and optic cup were extracted on the bases of the previously observed values of the statistical parameters. The irrelevant information was discarded and after that cup to disc ratio was computed for timely diagnosing of glaucoma. The above described method was more powerful and needs less computational cost, without composing the accuracy of the outcomes.

CUP-to-Disc ratio: The extracted optic disc and optic cup also having some extra information in form of noise when it was extracted from the previous method. SO it was necessary to deduce that noise or unwanted information for the exact result of the cup to disc ratio calculation.

Liu. [12] Proposed the execution of color intensity based approach against threshold based level set method for the segmentation of the optic cup. Here for the extraction of the optic disc the variation level set algorithm was used. Because of the Availability of the interwoven blood vessels inside the region of interest, the smoothing was carried out with the use of direct ellipse fitting algorithm to deduct the unwanted area on the boundary of the optic disc. The extraction of the optic cup was significantly more provoking than

the optic disc because of the unwanted blood vessels available inside the region and also the intensity difference between the optic disc and the optic cup region was least.

C. The steps suggested for detection were as follows:

- 1) Optic Disc determination
- 2) Variation Level Set algorithm for the
- 3) extraction of optic disc
- 4) Optic Cup determination
- 5) Color Intensity-based Threshold
- 6) Threshold level set approach

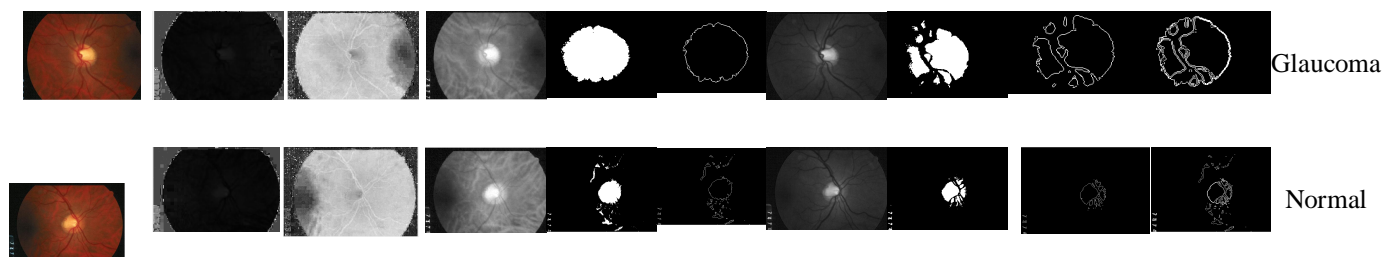
Then based on the extracted optic disc and optic cup, the computation of the cup to disc ratio was carried out and the estimation of that ratio the Images were classified with or without glaucoma.

TABLE I: Different methodologies used for detection of Glaucoma

| Sr. No | Methods | Database | Results |
|--------|---|---------------------------------------|---|
| 1. | high pass filtering and morphological operation[7] | HRF, STARE, DRIVE Database | ISNT ratio will be in the range 2.166 ± 0.19 for normal persons and 1.755 ± 0.08 for Glaucoma affected patients. Accuracy is 0.931 with a sensitivity specificity of 0.742 and 0.943. Threshold probing has an accuracy of 0.927. |
| 2 | Classification DiscreteWavelet Transform, ReceiverOperating Characteristics, Feature Selection [16] | RIMONE Database With 158 Images | Classification accuracy of RWF is 92.95% |
| 3 | Thresholding, Classification, Segmentation[9] | DRIVE, STARE, CHASE_DB1 | DRIVE average accuracy of $(94.43 \pm 0.14)\%$, Se= 0.7630, Sp=0.9764 and Acc=0.9463 STARE average accuracy of $(93.26 \pm 4.53)\%$, Se=0.8440, Sp=0.9476 and Acc=0.9326 CHASE_DB1 average accuracy of $(92.98 \pm 0.21)\%$,Se=0.7630, Sp=0.9764 and Acc=0.9463. |
| 4 | Segmentation, Classification, Histrogram Matching. [5] | DRIVE STARE Databases with 100 Images | <u>Classification rates</u> KNN-93.3 is abnormal,80.9 is normal BAYES-86.6 is abnormal,95.23 is normal SVM-100 is abnormal, 95.23 is normal . <u>Average classification Accuracy</u> KNN-94.15 on DRIVE ,95.24 on STARE BAYES-95.29 on DRIVE,94.76 on STARE SVM-94.27 on DRIVE ,95.19 on STARE |
| 5 | Thresholding, Classification, Segmentatio [7] | 54 Retinal images | Classification: Success Rate-89.18% ,33 images are shows correct results Sensitivity-88.00%, Accuracy-90.90% |

VI. RESULTS

| Original image | H plane image | S plane image | Vplane image | thresholding of v plane image | Extraction of optic Disc | Extraction of green plane image | thresholding of green plane image | Extraction of optic Cup | combined disc and cup for CDR value | classified |
|----------------|---------------|---------------|--------------|-------------------------------|--------------------------|---------------------------------|-----------------------------------|-------------------------|-------------------------------------|------------|
|----------------|---------------|---------------|--------------|-------------------------------|--------------------------|---------------------------------|-----------------------------------|-------------------------|-------------------------------------|------------|



VII. CONCLUSION

In this review paper, we have studied different techniques which were involved in detecting glaucoma. Glaucoma is one of the major eye diseases of blindness. According to preprocessing techniques like thresholding, morphological operation, ROI extraction, and classifiers such as KNN clustering, SVM, BAYES. These techniques will be of great help in the medical field to detect glaucoma at early stages as it requires very less data and expertise to test.

REFERENCES

- [1] Dnyaneshwari D.Patil, RameshManza, Gangadevi C. Bedke, "Diagnose Glaucoma by Proposed Image Processing Methods" International Journal of Computer Applications (0975 – 8887) Volume 106 – No.8, November 2014
- [2] Naz, S., Sheela N Rao "Glaucoma Detection in Color Fundus Images Using Cup to Disc Ratio" The International Journal Of Engineering And Science (IJES), ISSN (e): 2319 – 1813 ISSN (p): 2319 – 1805
- [3] Goli haveesh Govardhan hedge K, Bharghav J Bhatkalkar, Srikanth Prabhu, Sulatha Bhandary. "Glaucoma detection and its classification using image processing and fuzzy classification"
- [4] E.T.Gormus, N. Anantrasirichai, M.Bundy, I. Erchova, N.White, J.Fergusson, J.Morgan, L.B.Nicholson, A.Achim "Exploiting Texture Information in Diagnosing Glaucoma". 978-1-5090-6494-6/17/\$31.00 © 2017 IEEE
- [5] Kavitha, S., S. Karthikeyan, and K. Duraiswamy. "Early detection of glaucoma in retinal images using cup to disc ratio." In Computing Communication and Networking Technologies (ICCCNT), 2010 International Conference on, pp. 1-5. IEEE, 2010
- [6] B. Naveen Kumar, R.P. Chauhan, Nidhi Dahiya. School of Biomedical Engineering, National Institute of Technology Kurukshetra, India "Detection of Glaucoma using Image processing techniques: A Review" 978-1-4673-6621-2/16/\$31.00 © 2016 IEEE
- [7] Kumar G S. "Blood Vessel Segmentation in Fundus Images and Detection of Glaucoma" 2016 International Conference on Communication Systems and Networks (CommNet) | 21-23 July 2016 | Trivandrum
- [8] Chetan Tulasigeri, M Irulappan "An Advanced thresholding algorithm for diagnosis of glaucoma in fundus images". IEEE International Conference On Recent Trends In Electronics Information Communication Technology, May 20-21, 2016, India . 978-1-5090-0774-5/16/\$31.00 © 2016 IEEE Agaiwal, Ayushi, Shradha Gulia, Somal Chaudhary, Malay Kishore Dutta, Radim Burget, and Kamil Riha. "Automatic glaucoma detection using adaptive threshold based technique in fundus image." In Telecommunications and Signal Processing (TSP), 2015 38th International Conference on, pp. 416–420. IEEE, 2015
- [9] Wong, D. W. K., J. Liu, J. H. Lim, X. Jia, F. Yin, H. Li, and T. Y. Wong. "Level-set based automatic cup-to-disc ratio determination using retinal fundus images in ARGALI." In Engineering in Medicine and Biology Society, 2008. EMBS 2008. 30th Annual International Conference of the IEEE, pp. 2266–2269. IEEE, 2008
- [10] Chanwimaluang, Thitiporn, and Guoliang Fan. "An efficient blood vessel detection algorithm for retinal images using local entropy thresholding." In Circuits and Systems, 2003. ISCAS'03. Proceedings of the 2003 International Symposium on, vol. 5, pp. V-V. IEEE, 2003
- [11] Liu, J. D. W. K., Wong, J. H. Lim, X. Jia, F. Yin, H. Li, W. Xiong, and T. Y. Wong. "Optic cup and disk extraction from retinal fundus images for determination of cup-to-disc ratio." In Industrial Electronics and Applications, 2008. ICIEA 2008. 3rd IEEE Conference on, pp. 1828–1832. IEEE, 2008
- [12] Fauzia Khan, Shoaib A. Khan, Ubaid Ullah Yasin, Ihtisham ul Haq, Usman Qamar, "Detection of Glaucoma Using Retinal Fundus Images" the 2013 Biomedical Engineering International Conference (BMEiCON-2013) 978-1-4799-1467-8/13/\$31.00 © 2013 IEEE
- [13] K. Narasimhan, K. Vijayarekha, K.A. Jogi Narayana, P. Siva Prasad and V. Satish Kumar. "Glaucoma Detection From Fundus Image Using OpenCV" Journal of Applied Sciences, Engineering and Technology 4(24): 5459-5463, 2012 ISSN: 2040-7467
- [14] Gangadevi C. Bedke, "Diagnose Glaucoma by Proposed Image Processing Methods" Dnyaneshwari D.Patil International Journal of Computer Applications (0975 – 8887) Volume 106 – No.8, November 2014
- [15] Muhammad Salman Haleem, Liangxiu Han, Jano van Hemert and Alan Fleming "Glaucoma Classification using Regional Wavelet Features of the ONH and its Surroundings" 978-1-4244-9270-1/15/\$31.00 © 2015 IEEE



10.22214/IJRASET



45.98



IMPACT FACTOR:
7.129



IMPACT FACTOR:
7.429



INTERNATIONAL JOURNAL FOR RESEARCH

IN APPLIED SCIENCE & ENGINEERING TECHNOLOGY

Call : 08813907089  (24*7 Support on Whatsapp)