



iJRASET

International Journal For Research in
Applied Science and Engineering Technology



INTERNATIONAL JOURNAL FOR RESEARCH

IN APPLIED SCIENCE & ENGINEERING TECHNOLOGY

Volume: 7 Issue: I Month of publication: January 2019

DOI: <http://doi.org/10.22214/ijraset.2019.1139>

www.ijraset.com

Call:  08813907089

E-mail ID: ijraset@gmail.com

Hepatoprotective Activity of Cochlospermum Religiosum Leaves Extract against CCl₄ and Ethanol Induced Hepatic Damage in Rats

Shukla Pawandeep¹, Patel Rakesh², Saraswat Rohit³

^{1,3}Department of Pharmaceutical Sciences, OPJS University, Churu, Rajasthan, India

²School of Pharmacy, Dr. A.P.J. Abdul Kalam University, Indore, M.P., India

Abstract: Liver disease is one of the fatal diseases. Medicinal plants may serve as one of the best sources of remedies for treatment of liver disease. Identification of a potential therapeutic agent for protection of liver from hepatotoxins provides a useful way for the prevention of liver related illnesses. Effect of *Cochlospermum religiosum* leaves aqueous and ethanolic extracts were studied on CCl₄ and ethanol induced hepatic damage in rats. *Cochlospermum religiosum* was found to protect the rats from hepatotoxic action of CCl₄ and ethanol as evidenced by significant reduction in the elevated serum enzyme levels. Histopathological studies showed marked reduction in fatty degeneration in animals receiving *Cochlospermum religiosum* along with CCl₄ and ethanol as compared to the control group. It is stipulated that the extract treated groups were partially protected from hepatic cell damage caused by CCl₄ and ethanol.

Keywords: *Cochlospermum religiosum*, Therapeutic agent, CCl₄, Ethanol, Hepatotoxins

I. INTRODUCTION

Hepatic damage is still a worldwide health problem. Unfortunately, conventional or synthetic drugs used in the treatment of liver diseases are inadequate and sometimes can have serious side effects.¹ In the absence of a reliable liver protective drug in modern medicine there are a number of medicinal preparations in Ayurveda recommended for the treatment of liver disorders.² In view of severe undesirable side effects of synthetic agents, there is growing focus to follow systematic research methodology and to evaluate scientific basis for the traditional herbal medicines that are claimed to possess hepatoprotective activity.

Cochlospermum religiosum is a very beneficial tree and is used from very ancient times in India for curing a lot of ailments. Gum of *Cochlospermum religiosum* is used for stomachic, sedative, gonorrhea, syphilis and asthma. Paste of stem bark is applied over the bone fractured areas.³ The herb vendors sell the bark of *Cochlospermum religiosum* as a remedy to diabetes. It is used in combination with kalimirch.⁴ Powder of bark is used with water during jaundice.⁵

The study was conducted to evaluate the traditional use of *Cochlospermum religiosum* as hepatoprotective against CCl₄ and ethanol induced hepatotoxicity in rats.

II. MATERIALS AND METHODS

A. Plant Material

The leaves of *Cochlospermum religiosum* were collected in the month of July 2016 from local areas of Indore (M.P.) and were identified and authenticated by Dr. S.N. Dwivedi, Prof. and Head, Department of Botany, Janata PG College, A.P.S. University, Rewa, M.P. and deposited in our Laboratory, Voucher specimen No. J/BOT/H-138.

The leaves of *Cochlospermum religiosum* were dried under shade and then powdered with a mechanical grinder. The powders were passed through sieve No. 40 and stored in an airtight container for further uses.

B. Preparation of Extract

The dried powder of leaves of *Cochlospermum religiosum* were extracted with Ethanol (95%) in a soxhlet apparatus. Aqueous extract was prepared by cold maceration process by using separate quantity of powder. The solvents were removed by distillation under reduced pressure and the resulting semisolid mass was vacuum dried using rotary flash evaporator.

C. Drugs and Chemicals

CCl₄ was purchased from the local market of Indore (M.P.). Ethanol is also purchased from the Dawa Bazar, Indore (M.P.).

D. Animals

Male Wistar rats weighing 100-120 gms were used for this study. The animals were kept in polypropylene cages and maintained at $25 \pm 5^\circ\text{C}$ and $60 \pm 5\%$ humidity under 12 h light/dark cycle. The animals were allowed free access standard pellet diet and water. The animal experiment was performed according to the guidelines laid by Institutional Animal Ethical Committee (IAEC).

E. Acute Toxicity Study

Acute toxicity study was performed for the ethanol extract of leaves of *Cochlospermum religiosum* according to the Organisation for Economic Co-operation and Development guidelines (OECD)-No. 423 for acute toxic classic method.⁶ Three male Wistar albino rats were used for each step in this study. The animals were kept fasting for overnight only on water, after which the extracts were administered intra-gastrically at different doses of 5, 50, 300 and 2000 mg/kg. Food and water was further withheld for 1 h after drug administration.

F. Hepatoprotective Activity

1) *Experimental Animal*: Albino rats (100-120 gms) used in the present studies were procured from listed suppliers of Indore (M. P.), India. The animals were fed with standard pellet diet (Hindustan lever Ltd. Bangalore) and water *ad libitum*. All the animals were acclimatized for a week before use.

a) *CCl₄ Induced Model*: The rats were divided into 5 groups of 3 animals in each.

Group I : Received vehicle Gum acacia (5mg/kg.p.o) for 7 days, and served as normal control.

Group II: Received vehicle Gum acacia (5 mg/kg p.o) for 7 days once daily. Carbon tetrachloride 1ml/kg in 50% v/v olive oil on 7th day.

Group III: Received standard drug Silymarin (25 mg/kg) for 7 days once daily, CCl₄ 1ml/kg in 50% v/v olive oil on 7th day.

Group IV: Received aqueous extract of leaves of *Cochlospermum religiosum* 250mg/kg) for 7 days once daily, CCl₄ 1ml/kg in 50% v/v olive oil on 7th day.

Group V: Received ethanolic extract of leaves of *Cochlospermum religiosum* 250mg/kg) for 7 days once daily, CCl₄ 1ml/kg in 50% v/v olive oil on 7th day.

On the 7th day food and water were withdrawn after giving the last doses of aqueous and ethanolic extracts. After 36 hours the blood samples were collected and allowed to clot and serum was separated by centrifuge at 2500 rpm for 15 min and analyzed for various biochemical parameters.

i) *Assessment of Liver Function*: The liver was removed and weighed. Biochemical parameters i.e., Serum glutamic Pyruvate transaminase (SGPT), serum Glutamic Oxaloacetic Transaminase (SGOT), Alkaline phosphatase (ALP) were analyzed according to the reported methods.

ii) *Histopathological Studies*: Liver slices fixed for 12 hrs in Bouin's solution were processed for paraffin embedding following standard micro technique. 5 μ section of the livers stained with alum haematoxylin and eosin, were observed microscopically for histopathological changes i.e., normal liver, damaged and recovered liver were studied and compared.

b) Ethanol Induced Model

The rats were divided into 5 groups of 3 animals in each.

Group I : Received vehicle gum acacia (5mg/kg.p.o) for 5 days, and served as normal control.

Group II: Received vehicle gum acacia (5 mg/kg p.o) for 5 days once daily 50% Ethanol 5ml/kg on 5th day, and served as disease control.

Group III: Received Silymarin (25 mg/kg) for 5 days once daily, 50% Ethanol 5ml/kg on 5th day.

Group IV: Received aqueous extract of leaves of *Cochlospermum religiosum* (250mg/kg) for 5 days once daily and 50% Ethanol 5ml/kg on 5th day.

Group V: Received ethanolic extract of leaves of *Cochlospermum religiosum* (250mg/kg) for 5 days once daily and 50% Ethanol 5ml/kg on 5th day.

On the 5th day food and water were withdrawn after giving the last dose of aqueous and ethanolic extracts. After 24 hours the blood samples were collected and allowed to clot and serum was separated by centrifuge at 2500 rpm for 15 min and analyzed for various biochemical parameters.

G. Assessment of Liver Function

The liver was removed and weighed. Biochemical parameters i.e., Serum glutamic Pyruvate transaminase (SGPT), serum Glutamic Oxaloacetic Transaminase (SGOT), Alkaline phosphatase (ALP) were analyzed according to the reported methods.

H. Histopathological Studies

Liver slices fixed for 12 hrs in Bouin's solution were processed for paraffin embedding following standard micro technique. 5 μ section of the livers stained with alum haematoxylin and eosin, were observed microscopically for histopathological changes i.e., normal liver, damaged and recovered liver were studied and compared.

I. Hepatoprotective studies (CCl₄ Induced Model)

Liver plays a key role in regulation of physiological processes. It is involved in several functions such as metabolism, secretion and storage. Furthermore detoxification of a variety of drugs and xenobiotics occurs in liver. The bile secreted by the liver has, among other things, an important role in digestion. Liver diseases are the most serious ailments.

The results of biochemical parameters revealed that the elevation of enzyme level in CCl₄ treated group, are almost restored to the normal level in the extract treated group.

J. Effect on SGPT

Ethanollic extract and aqueous extract of leaves of *Cochlospermum religiosum* showed significant hepatoprotective activity as they reduced SGPT to 92.81 ± 4.32 and 90.36 ± 7.96 as compared to the hepatotoxic control 152.90 ± 3.26 and hence the extracts of leaves of *Cochlospermum religiosum* showed significant hepatoprotective activity. The results of treatment with extract of *Cochlospermum religiosum* are tabulated in Table No. 1.

SGPT is a cytosolic enzyme primarily present in the liver. The level of SGPT in serum increase due to leakage of this cellular enzyme into plasma by CCl₄ induced hepatic injury. Serum level of SGPT can increase due to damage of the tissue producing acute hepatic necrosis. Since the extract of *Cochlospermum religiosum* significantly reduced the level of SGPT, this suggests that the extracts possess significant hepatoprotective activity.

K. Effect on SGOT

Ethanollic and aqueous extract of leaves of *Cochlospermum religiosum* showed significant hepatoprotective activity as they reduced SGOT to 206.84 ± 7.32 and 202.36 ± 8.28 as compared to the hepatotoxic control 345.24 ± 9.86 and hence the extracts showed significant hepatoprotective activity. The results of treatment with extracts of leaves of *Cochlospermum religiosum* are tabulated in Table No. 1.

SGOT is a mitochondrial enzyme released from heart, liver, skeletal muscle and kidney. Liver toxicity elevated the SGOT level in serum due to the damage to the tissue producing acute necrosis such as several viral hepatitis and acute cholestasis. Since the extract of *Cochlospermum religiosum* significantly reduced the level of SGOT, this suggests that the extracts possess significant hepatoprotective activity.

L. Effect on ALP

Ethanollic and aqueous extract of leaves of *Cochlospermum religiosum* showed significant hepatoprotective activity as they reduced ALP to 207.22 ± 9.55 and 201.66 ± 7.84 as compared to the hepatotoxic control 358.96 ± 8.80 hence the extract of leaves of *Cochlospermum religiosum* showed significant hepatoprotective activity. The results of treatment with extracts of *Cochlospermum religiosum* are tabulated in Table No. 1.

In case of toxic liver, alkaline phosphate levels are very high, which may be due to defective hepatic excretion or by increased production of ALP by hepatic parenchyma or duct cells. Since the extract of *Cochlospermum religiosum* significantly reduced the level of ALP, this suggests that the extracts possess significant hepatoprotective activity.

M. Effect On Liver Weight

The liver weight of animals treated with Ethanollic and aqueous extracts of the leaves of *Cochlospermum religiosum* were compared with that of the standard drug Silymarin (25mg/kg) treated ones. The Ethanollic and aqueous extracts of the leaves of *Cochlospermum religiosum* exhibited significant decrease in the weight of liver as that of the standard drug Silymarin and thus suggest that the both extracts of leaves of *Cochlospermum religiosum* possess significant hepatoprotective activity.

Table No. 1

Effect of aqueous and ethanolic extracts of leaves of *Cochlospermum religiosum* on CCl₄ induced hepatotoxicity in rats

Treatment	Total Bilirubin (mg%)	Direct Bilirubin (mg%)	SGOT (μ /min/l)	SGPT (μ /min/l)	ALP (μ /min/l)
Normal	0.44 \pm 0.20	0.43 \pm 0.48	178.24 \pm 2.6	77.33 \pm 3.44	192.74 \pm 6.3
Induced (CCl ₄ 2g/kg)	8.79 \pm 2.44	7.49 \pm 3.33	345.24 \pm 9.86	152.90 \pm 3.26	358.86 \pm 8.80
Standard (Silymarin 25mg/kg)	0.34 \pm 4.38**	0.39 \pm 0.20**	197.88 \pm 9.43**	87.34 \pm 8.28**	198.12 \pm 10.45**
Aqueous extract (250mg/kg)	0.54 \pm .46**	0.46 \pm 0.45**	202.36 \pm 8.28**	90.36 \pm 7.96**	201.66 \pm 7.84**
Ethanolic extract (250mg/kg)	0.56 \pm 4.43*	0.51 \pm 0.64*	206.84 \pm 7.32*	92.81 \pm 4.32*	207.22 \pm 9.55*

Values are mean \pm SEM, n= 6. (One way ANOVA Followed by Dunnette multiple Comparisons test). Statistically significance of * P<0.01, ** P<0.001, when compared with respective control

Table no. 2.

Effect of aqueous and ethanolic extracts of leaves of *Cochlospermum religiosum* on liver weight variation of CCl₄ induced hepatotoxicity in rats

Treatment	Liver weight in g/100g
Normal	6.62 \pm 0.47
Induced (CCl ₄ 2g/kg)	7.98 \pm 0.56
Standard (Silymarin 25mg/kg)	7.20 \pm 0.28**
Aqueous extract (250mg/kg)	7.24 \pm 0.23**
Ethanolic extract (250mg/kg)	7.18 \pm 0.68*

Values are mean \pm SEM, n= 6. (One way ANOVA Followed by Dunnette multiple Comparisons test). Statistically significance of * P<0.01, ** P<0.001, when compared with respective control.

N. Hepatoprotective Studies (Ethanol Induced Model)

The result of biochemical parameter revealed that the elevation of enzyme level in Ethanol induced treated group almost restored to the normal level in the extracts treated groups.

O. Effect on SGPT

Ethanolic extract and aqueous extract of leaves of *Cochlospermum religiosum* showed significant hepatoprotective activity as they reduced SGPT to 76.56 \pm 3.44 and 73.22 \pm 1.80 as compared to the hepatotoxic control 111.8 \pm 3.56 and hence the extracts of *Cochlospermum religiosum* showed significant hepatoprotective activity. The results of treatment with extracts of *Cochlospermum religiosum* are tabulated in Table No. 3. SGPT is a cytosolic enzyme primarily present in the liver. The level of SGPT in serum increase due to leakage of this cellular enzyme into plasma by Ethanol induced hepatic injury. Serum level of SGPT can increase due to damage of the tissue producing acute hepatic necrosis. Since the extract of *Cochlospermum religiosum* significantly reduced the level of SGPT, this suggests that the extracts possess significant hepatoprotective activity.

P. Effect on SGOT

Ethanolic extract and aqueous extract of leaves of *Cochlospermum religiosum* showed significant hepatoprotective activity as they reduced SGOT to 201.87 \pm 7.98 and 199.86 \pm 4.32 as compared to the hepatotoxic control 297.66 \pm 3.88 and hence the extracts of *Cochlospermum religiosum* showed significant hepatoprotective activity. The results of treatment with extracts of *Cochlospermum religiosum* are tabulated in Table No. 3.

SGOT is a mitochondrial enzyme released from heart, liver, skeletal muscle and kidney. Liver toxicity elevated the SGOT level in serum due to the damage to the tissue producing acute necrosis such as several viral hepatitis and acute cholestasis. Since the extract of *Cochlospermum religiosum* significantly reduced the level of SGOT, this suggests that the extracts possess significant hepatoprotective activity.

Q. Effect on ALP

Ethanollic and aqueous extract of leaves of *Cochlospermum religiosum* showed significant hepatoprotective activity as they reduced ALP to 206.24 ± 6.08 and 204.14 ± 3.56 as compared to the hepatotoxic control 317.44 ± 10.64 and hence the extracts of *Cochlospermum religiosum* showed significant hepatoprotective activity. The results of treatment with extracts of *Cochlospermum religiosum* are tabulated in Table No. 3.

In case of toxic liver, alkaline phosphate levels are very high, which may be due to defective hepatic excretion or by increased production of ALP by hepatic parenchyma or duct cells. Since the extracts of *Cochlospermum religiosum* significantly reduced the level of ALP, this suggests that the extracts possess significant hepatoprotective activity.

R. Effect On Liver Weight

The liver weight of animals treated with ethanollic and aqueous extracts of the leaves of *Cochlospermum religiosum* were compared with that of the standard drug silymarin (25mg/kg) treated ones. The ethanollic and aqueous extracts of the leaves of *Cochlospermum religiosum* exhibited significant decrease in the weight of liver as that of the standard drug Silymarin and thus suggest that the extracts of *Cochlospermum religiosum* possess significant hepatoprotective activity.

III. RESULTS AND DISCUSSION

Table No. 3

Effect of aqueous and ethanollic extracts of leaves of *Cochlospermum religiosum* on ethanol induced hepatotoxicity in rats

Treatment	Total Bilirubin(mg%)	Direct Bilirubin(mg%)	SGOT (μ /min/l)	SGPT (μ /min/l)	ALP (μ /min/l)
Normal	0.46 ± 0.22	0.42 ± 0.68	184.04 ± 2.4	78.42 ± 2.42	193.0 ± 6.4
Control (Ethanol 1g/kg)	9.82 ± 2.82	6.28 ± 3.36	297.66 ± 3.88	111.8 ± 3.56	317.44 ± 10.64
Standard (Silymarin 25mg/kg)	$0.54 \pm 0.02^{**}$	$0.42 \pm 2.86^{**}$	$186.48 \pm 8.52^{**}$	$68.42 \pm 8.46^{**}$	$196.00 \pm 8.24^{**}$
Aqueous extract (250mg/kg)	$0.58 \pm 0.44^{**}$	$0.48 \pm 0.46^{**}$	199.86 ± 4.32	$73.22 \pm 1.80^{**}$	$204.14 \pm 3.56^{**}$
Ethanollic extract (250mg/kg)	$0.60 \pm 0.22^*$	$0.54 \pm 0.24^*$	$201.87 \pm 7.98^*$	$76.56 \pm 3.44^*$	$206.24 \pm 6.08^*$

Values are mean \pm SEM, n= 6. (One way ANOVA Followed by Dunnette multiple Comparisons test). Statistically significance of * $P < 0.01$, ** $P < 0.001$, when compared with respective control.

Table No. 4

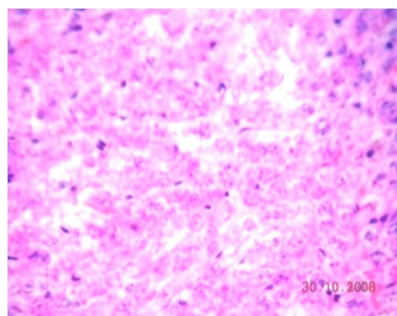
Effect of aqueous and Ethanollic extracts of leaves of *Cochlospermum religiosum* on liver weight variation of Ethanol induced hepatotoxicity in rats

Treatment	Liver weight in g/100g
Normal	6.65 ± 0.64
Induced (Ethanol 1g/kg)	7.68 ± 0.12
Standard (Silymarin 25mg/kg)	$7.20 \pm 0.22^{**}$
Aqueous extract (250mg/kg)	$7.16 \pm 0.24^{**}$
Ethanollic extract (250mg/kg)	$7.18 \pm 0.42^*$

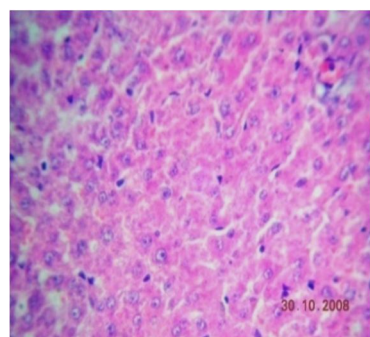
Values are mean \pm SEM, n= 6. (One way ANOVA Followed by Dunnette multiple Comparisons test). Statistically significance of * $P < 0.01$, ** $P < 0.001$, when compared with respective control.

A. Figure No. 1. Diagram Showing Histopathologic Section Of Liver Of Rats In CCL_4 Induced Hepatotoxicity

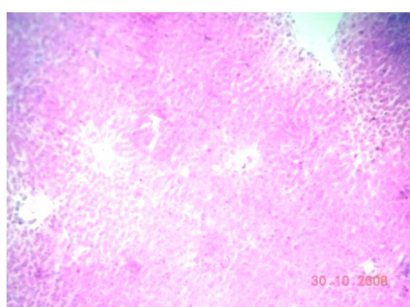
- 1) Normal: The architecture is normal. The central veins, sinusoids and portal triads appear normal. The hepatocytes show moderate cytoplasm and round to oval nuclei. There is no periportal inflammation



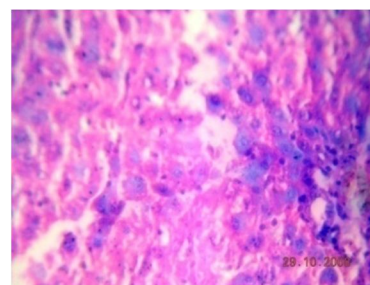
- 2) CCl_4 induced (500mg/kg): The central veins show dilatation and congestion. The hepatocytes show feathery degeneration. The portal triads show mild peri-portal inflammation composed of lymphocytes.



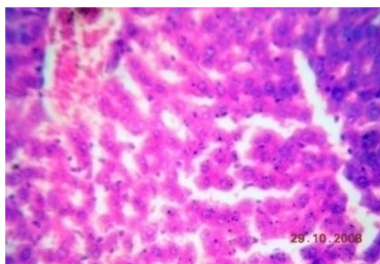
- 3) Silymarin (25mg/kg): The central veins appear normal. The hepatocytes show feathery degeneration. The portal triads show mild peri-portal inflammation composed of lymphocytes.



- 4) Aqueous Extract (250mg/Kg): The hepatocytes show moderate cytoplasm and moderately enlarged pleomorphic and hyperchromatic nuclei. The portal triads show mild peri-portal inflammation composed of lymphocytes. The central veins are normal.

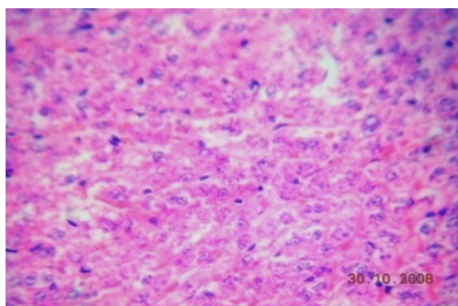


- 5) *Ethanollic Extract (250mg/Kg)*: The central veins show mild dilatation and congestion. The hepatocytes are normal. The portal triads appear normal

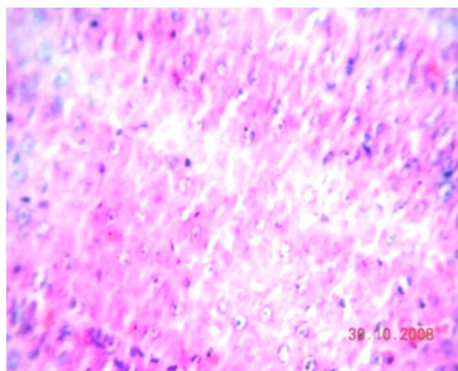


B. Figure no. 2. Diagram Showing Histopathologic Section Of Liver Of Rats In Ethanol Induced Hepatotoxicity

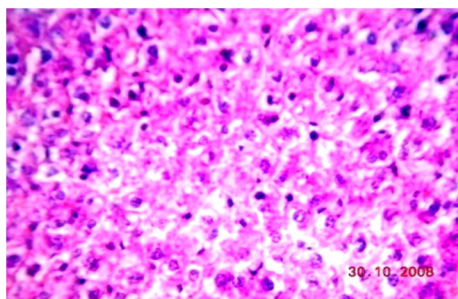
- 1) *Normal*: The architecture is normal. The central veins, sinusoids and portal triads appear normal. The hepatocytes show moderate cytoplasm and round to oval nuclei. There is no periportal inflammation



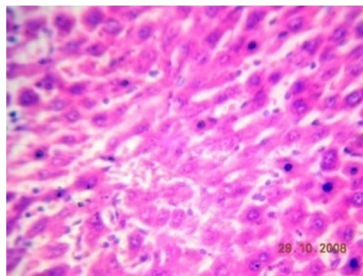
- 2) *Ethanol Induced (1g/Kg)*: The central veins show mild dilatation and congestion. The hepatocytes are normal. The portal triads appear normal.



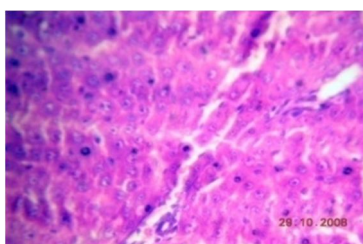
- 3) *Silymarin (25mg/kg)*: Section shows large dilated and congested central veins. The hepatocytes are normal. The portal triads appear normal.



- 4) *Aqueous Extract (250mg/Kg)*: The central veins appear normal. The hepatocytes show moderate cytoplasm and enlarged pleomorphic nuclei. The portal triads are normal.



- 5) *Ethanol extract (250mg/kg)*: The architecture is normal. The hepatocytes show normal appearance with moderate cytoplasm and round nuclei. There are many mitotic figures within regenerating hepatocytes. The portal tracts are normal.



IV. CONCLUSION

In conclusion, acute toxicity study of both extracts of *Cochlospermum religiosum* has been done. The ethanolic and aqueous extracts of *Cochlospermum religiosum* showed hepatoprotective activity against CCl_4 and ethanol induced model. There is no previous study for hepatoprotective activity for *Cochlospermum religiosum*. This plant can be considered as a good source of hepatoprotective drugs.

REFERENCES

- [1] Guntupalli M, Mohana Raoa, Chandana V, Raoa, Palpu Pushpangadana, Annie Shirwaikarb; Hepatoprotective effects of rubiadin, a major constituent of *Rubia cordifolia* Linn., *Journal of Ethnopharmacology*, 2006; 103 (3): 484-490.
- [2] Chatterjee TK; Medicinal plants with hepatoprotective properties in *Herbal Options*. 3rd edition, Books and Allied (P) Ltd., Calcutta, 2000: 135.
- [3] J. Lenin Bapuji, S. Venkataratnam, *Ethno. Leaflets*: 13, 388-398 (2009).
- [4] Pankaj oudhia, *Indian herbal research and methods*. (1995).
- [5] K.D.Dinesh, A. Jain, *Plan Tiss. Org. Cul* : 71, 223-229 (2010).
- [6] Irwin. Science. 1962, 136:123.
- [7] Rao KS, Mishra SH. Screening of anti-inflammatory and hepatoprotective activities of alantolactone isolated from the roots of *Inula racemosa*. *Ind Drugs*. 1997; 34: 571-5.
- [8] Carleton G, Harry A, Montgomery L. *General histology procedure in Carleton's histology technique-5 E d*. Oxford University press. 1980; 321:235.



10.22214/IJRASET



45.98



IMPACT FACTOR:
7.129



IMPACT FACTOR:
7.429



INTERNATIONAL JOURNAL FOR RESEARCH

IN APPLIED SCIENCE & ENGINEERING TECHNOLOGY

Call : 08813907089  (24*7 Support on Whatsapp)