



IJRASET

International Journal For Research in
Applied Science and Engineering Technology



INTERNATIONAL JOURNAL FOR RESEARCH

IN APPLIED SCIENCE & ENGINEERING TECHNOLOGY

Volume: 7 Issue: IV Month of publication: April 2019

DOI: <https://doi.org/10.22214/ijraset.2019.4416>

www.ijraset.com

Call:  08813907089

E-mail ID: ijraset@gmail.com



Present Scenario of Breast Volume Identification and Detection

Prof. Samir Kumar Bandyopadhyay

Advisor to Chancellor, JIS University, India

Abstract: *Computer technology has had a tremendous impact on medical imaging. Breast volume calculation plays an important role in breast cancer diagnostics and it also plays an important part in rehabilitation surgery for reconstruction of breast after surgery and cosmetic surgeries of breast. Breast volume calculations are carried out using complex procedures that also include surgical means, called mastectomy. But it is very important to calculate the same non-invasively, for the decision making towards the successful treatment.*

Keywords: *Breast Cancer, Computer-Aided Diagnosis, CC and MLO*

I. INTRODUCTION

Breast cancer is growing throughout the world. The mortality rate is much higher in developing countries than in developed countries. The incidence is common in urban women than rural women. It may due to rapid change of lifestyles, there is a rising incidence of breast cancer in India. In India, the death toll due to breast cancer is increasing at a rapid pace. Primary prevention becomes impossible since the cause of breast cancer remains unknown.

Only early detection and diagnosis is the way of control but it is a major challenge in India due to lack of awareness and lethargy of the Indian women towards health care and regular check-up.

But the major obstacle in India is expensive health care system and unavailability of proper infrastructure, especially in breast cancer treatment.

Breast cancer screening is a professional medical examination performed to check women's breasts for abnormalities such as tumour and cysts while biopsy is the process to identify malignancies.

Several screening techniques can be used to examine the breast including Ultrasound imaging, which uses a band of high frequency sound waves to probe the breast, Magnetic Resonance Imaging (MRI), which probes the breast using powerful magnetic fields and Mammography, which produces X-ray images of the breast.

Among all screening associated with clinical breast examination, digital Mammography has been proved to be the most effective and reliable screening method for early breast tumour detection.

Computer-Aided Diagnosis (CAD) is a combining technology of digital image processing with medical image processing [1-2]. The initial part of any system is focused on identifying breast abnormalities in mammographic screening. Breast abnormalities detection using mammogram is a well-known field of research and some significant works have been carried out worldwide. During the interpretation process radiologists carefully search each image for any visual sign of abnormality. The images for various patients have different dynamics of intensity and present a weak contrast. The process needs both effective and efficient improvements over existing algorithms and introduces some innovative ideas based on image segmentation process to help the radiologists in making accurate interpretation of the digital mammograms.

It is also required to determine the future risk of breast cancer from digital mammographic images [3]. The exact cause of breast cancer is not identified but researches show that there are some morphological and anatomical characteristics which can be the indicators for future risk. There are some sporadic works has been done in this direction yet there is no comprehensive outcome available in the public domain. The characteristics features like asymmetry, volume and density are used in this research to predict the potential future risk factors [4-5].

Further it is needed to analyse the histopathological biopsy slides for confirmation of breast cancer. It is an absolutely new field in research. Digital microscopy is used in field of blood specimen analysis worldwide but its use in surgical biopsy slide analysis is rudimentary [6]. The entire process is shown in figure 1.

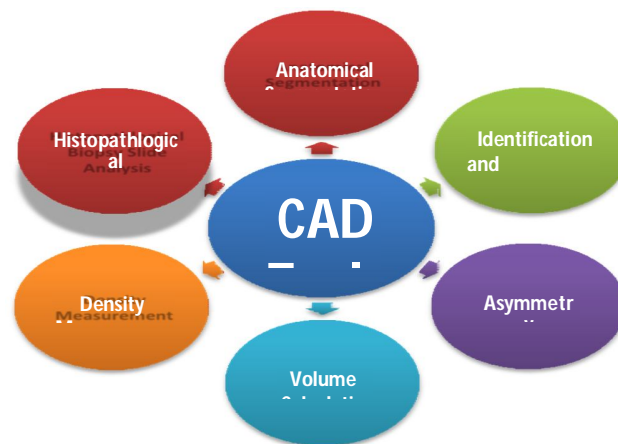


Figure 1 The schematic Diagram of Deliverables of CAD Tools

Using mammogram and other screening techniques can only detect the abnormalities; however, conclusion cannot be drawn from that observation. So, the CAD may be a detection tool but not a diagnosis tool without incorporating the histopathological part.

Present researches in breast cancer is not only restricted itself to detect the abnormalities from digital mammogram but also extends to identify the future risk factor and pre-processing of biopsy slide.

In the present scenario the detection method is based on mammogram analysis. The input for the process is raw digital mammogram images and output is the identification of abnormalities if present. The detection method can be divided into three sequential distinct subsections namely preparation, pre-processing, and abnormality identification.

The pre-processing phase is needed in order to improve the image quality and make the segmentation results more accurate. The implementation of this phase is done for two purposes as given below. The noise removal using Gaussian smoothing is also made in this process.

- 1) Artefact Removal
- 2) Image Orientation

The pre-processing phase consists of mammogram image registration and edge detection, pectoral muscle suppression, contour determination and anatomical segmentation. All these processes are mandatory, distinct and sequential in nature for further processing.

Mammogram screening also includes future risk determination. There are three proven risk markers that has been considered for future risk determination namely, asymmetry analysis, volume calculation and parenchymal density estimation. The preparation and pre-processing steps are pre-requisite for the elimination of these risks. The digital pathology or digital microscopy is very important for a fully automated real time CAD system. It is required to preprocess of histopathological slide image. It suppresses the insignificant portion from slide image and finally using colour polarisation to enhance the information of histopathological slide thus highlighting the cancer cells for easy identification of abnormalities by experts. Digital mammography is most reliable and cost effective way to determine breast volume. Digital mammography is most reliable and cost effective way to determine breast volume. This paper describes the process for breast volume calculation for detection of abnormality in breast.

II. LITERATURE REVIEW

Analysis of the breast cancer detection includes determination of quantitative, qualitative, comparative and complexity measures over a well known database consisting of mammogram images. A comprehensive and critical review of existing methods was first undertaken to establish the progress of research in the area.

In the course of literature review phase, it has been observed that several works that had been done using algebraic formulas or computerised algorithms to determine the volume of the complex structure like breast.

There are several interesting works that has been carried out to estimate breast volume by researchers of different field of studies. Some of the important works are like displacement methods [7-8], external casting [9], anthropometric measurements [10-11] and mammographic methods [12-15].

One of the early methods and path breaking research is proposed by researchers [16]. Here they used only the CC view of mammogram to calculate the volume. They visualised the breast like a cone with circular base. They considered the vertical line drawn from the nipple to base of the breast as height of cone and took half the distance of the sum of two parts formed on the base by the vertical line representing the height, as radius of the circular base. Some researchers have taken into consideration both CC and MLO view of mammogram [17]. They have also used cone as geometrical representation of breast but they differed from the other method regarding base of the cone. According to their study, base of the breast is elliptical in nature rather than a regular circle. For that they have cited their logic that width of CC and MLO view are not same. So, they replace the cone with circular base model by the cone with elliptical base model.

III. PROPOSED METHOD

Human organs like the breast is a complex geometrical structure that can be better represented as hemispherical dome with an elliptical base rather than a cone structure. The complexity further increases as it can be observed that the upper portion of the breast and the lower portion of the breast have different curvatures in the MLO view. So, the proposed method divides the breast into two parts along the plane that is formed by the longest perpendicular distance from chest wall to skin adjacent to the nipple. The upper part of the breast is the region that extends from lateral thoracic artery to the aforesaid plane. The lower part extends from the dividing plane to the infra-mammary fold. This is taken into consideration while proposing the method.

On merging the images obtained from Pectoral Muscle Boundary Detection Algorithm (PMBDA) and Breast Boundary Detection Algorithm (BBDA), the ROI of the Breast for mammogram images is obtained for both CC and MLO views. It is shown in figure 1.

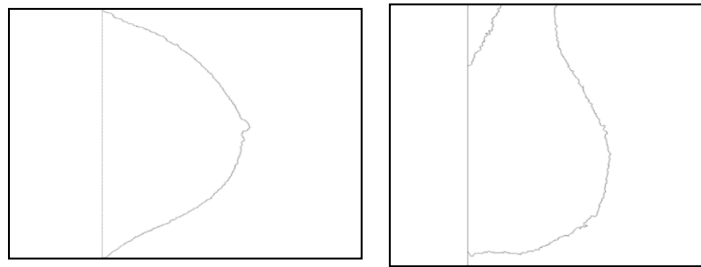


Figure 1 ROI of CC and MLO views of mammogram BXL of LLNL/UCSF database

The breast like any other human organ is a complex structure that is difficult to define as a specific geometric form. To calculate the volume, the three corresponding dimensions from the ROI of the CC and MLO views are needed. The two ROI images obtained from the above methods are two dimensional (2D) images but have two different perspectives. From the ROI image of the MLO view the height (h_{MLO}) and the width (w_{MLO}) can be obtained. Similarly, from the CC view of the ROI image the height (h_{CC}) and the width (w_{CC}) can be derived. The height in the MLO and CC views are of same value, so either of the ROI image to calculate the height can be considered. The width in CC and MLO views are the remaining two dimensions for calculating the volume of breast. The width in the MLO view can be defined as the region that extends from the point where the lateral thoracic artery enters the breast region to the point where skin crosses the pectoralis major, i.e. the infra-mammary fold. This fold is formed by the infra-mammary ridge, which is a band of fatty tissue formed by the folding over of the breast upon itself and is deeply connected to the sagging of breast in older women. To measure the extent of the breast the line adjoining these two points starting from the thoracic artery defined as point A to infra-mammary-fold defined as point B must be taken into consideration. A line AB has been drawn that forms the axis of the breast or w_{MLO} . This is shown in figure 2.

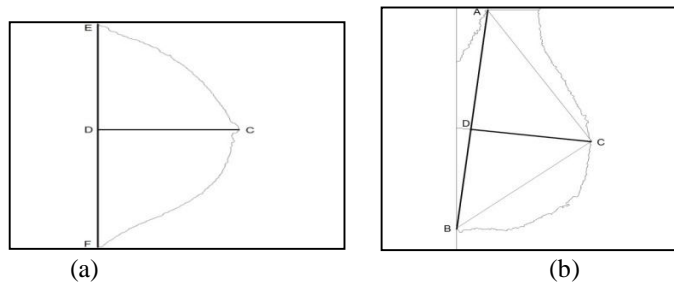


Figure 2 (a) CC view showing width (w_{CC}) i.e. EF and height (h_{CC}) i.e. CD and (b) MLO view showing width (w_{MLO}) i.e. AB and height (h_{MLO})

To calculate the height in MLO view h_{MLO} , the longest perpendicular distance from the chest wall to the skin adjacent to the nipple region is considered. The point is marked as C. This forms the largest cross sectional distance for the breast region. Now, it is needed to draw a line that is perpendicular to the line AB connecting C. First the slope has been calculated for line AB and then iterate through the points of line AB to the point where the value is the negative inverse of the slope AB and passes through C. The obtained point is named as D and lie on the line AB. The distance of CD is the value of h_{MLO} .

The breast ROI in the CC view appears as a semi-circular structure in 2D. The height in the CC view h_{CC} is longest perpendicular distance from the chest wall to skin adjacent to the nipple. The width in CC view is the distance between two lateral extremes. The two lateral extreme points are named as E and F. The distance EF corresponds to the w_{CC} value.

After merging the two ROI images of the breast in CC and MLO views, a three dimensional (3D) structure is achieved with three distinct values for the three corresponding dimensions. The h_{MLO} , w_{MLO} and w_{CC} are taken as the three values for calculating the volume. 3 D structure is shown in figure 3.

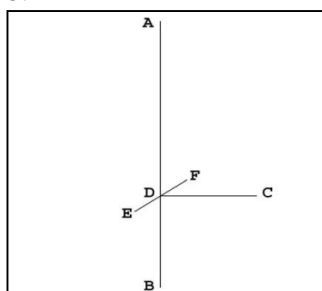


Figure 3 3D structure showing the h_{MLO} , w_{MLO} and w_{CC}

The obtained 3D structure gets divided into two unequal parts by the CD and EF plane due to $AD \neq DB$. On the CD and EF plane an ellipse can be drawn that is passing through the points E, C and F. It is shown in figure 4.

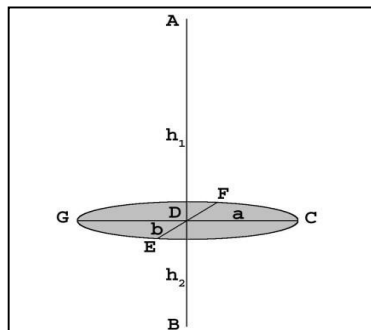


Figure 4 3D structure showing the elliptical base with radii of a and b, with $h_1 \neq h_2$ for AB

The breast being a complex structure is proposed by us as a pair of elliptical paraboloid sharing same elliptical base. Two elliptical paraboloids have been drawn facing each other on the same axis AB with the vertex A and B passing through point C, E and F and is shown in figure 5.

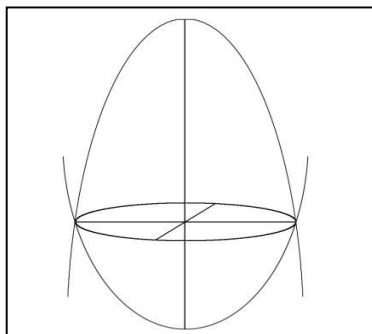


Figure 5 Proposed pair of elliptical paraboloid structure

The human breast assumes different shape during the different phases in life from puberty to old age. With increasing of age the breast sags with respect to the chest wall. So, the axis AB of the breast is not parallel to the chest wall but gets tilted on aging. So, the geometric representation also gets tilted on the axis AB as shown in figure 6 and figure 7.

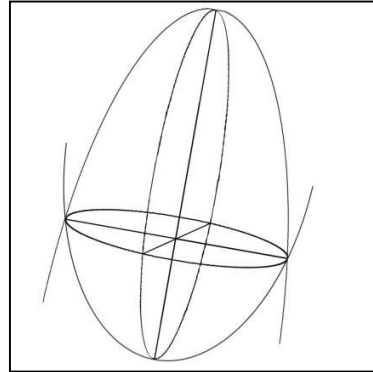


Figure 6 The proposed model tilted on AB axis

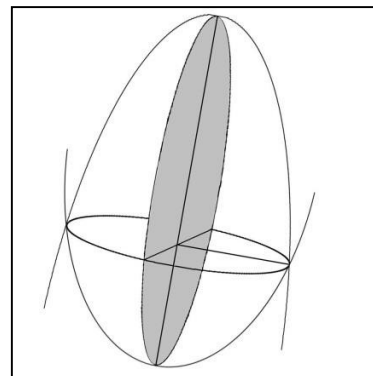


Figure 7 Plane of elimination

To resemble the complex breast structure, half of this proposed elliptical paraboloid structure is considered by eliminating the left half along the AB and EF plane. The final 3D structure for representation of breast is shown in figure 8.

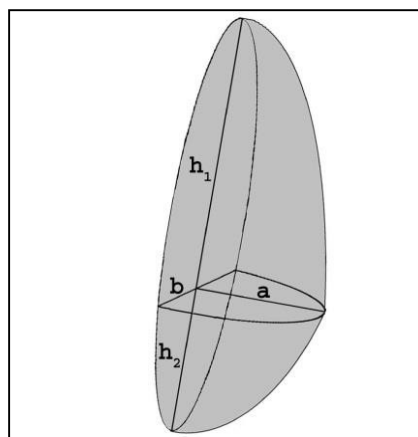


Figure 8 The final 3D structure for representation of breast

Now, to calculate the volume of the final elliptical paraboloid model where AD and DB are h_1 , h_2 . CD and FD are defined as a and b respectively.

Elliptical Paraboloid is such a structure that from one side, it is an elliptical in shape and from other two sides it has a parabolic shape but with a different eccentricity. It is elliptic shape when the figure is cut on a horizontal plane or the x-y plane. The Figure 9 shows Elliptical Paraboloid in X, Y and Z plane.

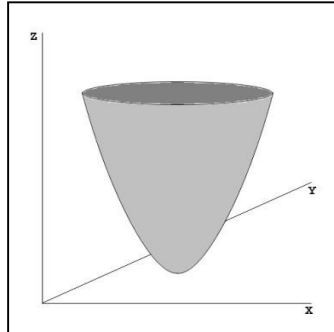


Figure 9 Elliptical paraboloid in 3D plane

To compute volume of Elliptical Paraboloid, triple integration has been used. This will be extremely complex to calculate. The best way to approach this problem is to slice the figure along the Z axis into differential volumes dz in thickness with the shape of an ellipse.

IV. EXPERIMENTAL RESULT

The proposed model has been implemented to calculate the volume for all set of mammograms in the LLNL/UCSF database. The database contains images for 50 patients with four image for each patient containing one pair for MLO and one pair for CC view. The results of three sets are cited below that are representative of different shape and size.

A. Case

The images of BFL of LLNL/UCSF database in CC and MLO views are used to calculate the volume. The original images are condensed by a factor of 4.7715 for CC and by 5.4824 for MLO respectively. So, for these two images the digitisation is 0.0167 cm and 0.0192 cm respectively. The calculated volume by the proposed algorithm is 975 cc. Experimental result on BFL of CC and MLO views is shown in figure 10.

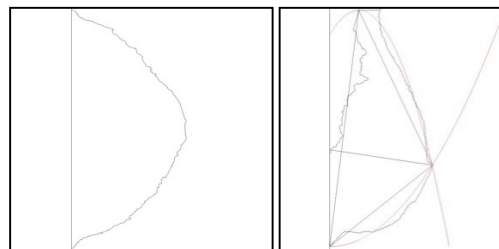


Figure 10 Experimental result on BFL of CC and MLO views

V. CONCLUSION

Human breast like any other organ of the human body is a multifaceted structure containing different tissues under-laying different organs. The breast also undergoes transformation during the life time of the female depending on the hormonal changes that occur from puberty through lactating mother to post menopause. During this time the shape and structure of the breast change significantly from a firm structure to a sagging structure. A sagged breast structure has been represented by a paraboloid structure having two half paraboloid placed on the same elliptical base. A formula has been also deduced for calculating the volume of the breast based on the CC and MLO views of the breast. Both these views are providing a 3D perspective to the breast and reconsidering the breast as a geometric model for calculation of the volume. The proposed model takes into consideration the curved structure of the breast and the sagging that occurs due to aging, while developing the model. It has been proved that the model takes into consideration a greater portion of the breast tissue for calculating the volume of the breast than other established methods. Accurate breast volume measure by computational method can benefit in cases of breast diagnostics, rehabilitation reconstruction surgeries, cosmetic surgeries and other related areas without the need of complex and painful procedures currently performed.



REFERENCES

- [1] Huynh, B.Q.; Li, H.; Giger, M.L., "Digital mammographic tumor classification using transfer learning from deep convolutional neural networks.", J. Med. Imaging, 2016.
- [2] Ting, F.F.; Tan, Y.J.; Sim, K.S., "Convolutional neural network improvement for breast cancer classification. ", Expert System, Appl. 2019.
- [3] Tsochatzidis, L.; Zagoris, K.; Arikidis, N.; Karahaliou, A.; Costaridou, L.; Pratikakis, I., "Computer-aided diagnosis of mammographic masses based on a supervised content-based image retrieval approach.", Pattern Recognition, 2017.
- [4] Czaplicka et al., "Automatic Breast-Line and Pectoral Muscle Segmentation", Schedae Informaticae, Vol. 20, 2011.
- [5] EtehadTavakol et al., "Application of K- and Fuzzy c-Means for Color Segmentation of Thermal Infrared Breast Images", Springer – Journal of Medical Systems, 2010.
- [6] MartI et al., "Automatic mammographic registration: towards the detection of abnormalities. Detection of linear structures in mammographic images", Medical Image Understanding and Analysis, 2001.
- [7] Bouman, "Volumetric measurement of the human breast and breast tissue before and during mammoplasty", British Journal of Plastic Surgery, 1970.
- [8] Ward et al, "The search for volumetric symmetry in reconstruction of the breast after mastectomy", British Journal of Plastic Surgery, 1986.
- [9] Campaigne et al, "Measurement of breast volume in females: description of a reliable method", Annals of Human Biology, 1979.
- [10] Smith et al, "Breast volume and anthropomorphic measurements: normal values", Plastic and Reconstructive Surgery, 1986.
- [11] Loughry et al, "Breast volume measurement of 598 women using biostereometric analysis", Annals of Plastic Surgery, 1989.
- [12] Katariya et al, "Breast volumes in cancer of the breast", British Journal of Cancer, 1974.
- [13] Stomper et al, "Analysis of parenchymal density on mammograms in 1353 women 25–79 years old", American Journal of Roentgenology, 1996.
- [14] Keddy et al, "Negative development xeroradiography of the breast: doses and clinical indications", British Journal of Radiology, 1980.
- [15] Kalbhen et al, "Mammographic determination of breast volume: comparing different methods", American Journal of Roentgenology, 1999.
- [16] Katariya et al, "Breast volumes in cancer of the breast", British Journal of Cancer, 1974.
- [17] Fung et al, "Mammographic Determination of Breast Volume by Elliptical Cone Estimation", World Journal of Surgery, 2010.



10.22214/IJRASET



45.98



IMPACT FACTOR:
7.129



IMPACT FACTOR:
7.429



INTERNATIONAL JOURNAL FOR RESEARCH

IN APPLIED SCIENCE & ENGINEERING TECHNOLOGY

Call : 08813907089  (24*7 Support on Whatsapp)