

A Review on Drug Eluting Stents in Treating Hepatic Artery Stenosis Post Liver Transplantation

Shilpa Nagod¹, Dr S.V Halse²

^{1,2}Research Scholar, Akkamahadevi Women's University, Vijayapura

Abstract: *Hepatocellular Carcinoma is one of the deadly diseases and when it is being spread to most of the parts of liver with tumor size being large, liver transplantation surgeries are done. The transplantation has its own cons which gives rise to new problems such as Hepatic Artery Stenosis. Hepatic artery stenosis (HAS) occurs in 5% to 11% of orthotopic liver transplants (OLTs) and can lead to hepatic artery thrombosis (HAT) [1-3]. Hepatic artery stenosis results in hepatic dysfunction and biliary complications. There could be bile duct necrosis. Thrombosis could cause liver failure. Implantation of drug eluting stents following percutaneous transluminal angioplasty has revealed a well-established technique for treating occlusions caused by the atherosclerotic plaque. This paper includes the discussion of how the drug-eluting stents have evolved.*

Keywords: *Drug-eluting stents, Hepatocellular Carcinoma, Hepatic Artery Stenosis, Liver Transplantation, Thrombosis*

I. INTRODUCTION

The hepatic artery provides blood flow to both the liver parenchyma and the biliary system and inadequate perfusion may have significant consequences. Hepatic artery stenosis (HAS) is a rare but important complication of orthotopic liver transplantation. Percutaneous transluminal angioplasty has been used in the past to treat artery occlusion (stenosis) due to atherosclerotic plaques. However, the frequent occurrence of re-occlusion (restenosis) of the treated vessel observed after intervention [4] indicated the requirement of alternative approaches.

That is when the Drug Eluting Stents came into picture. A drug-eluting stent (DES) is a metallic prosthesis (strut) implanted into the arterial wall and coated with a thin layer of biocompatible polymeric gel that encapsulates a therapeutic drug (coating). Such a drug, released in a controlled manner through a permeable membrane, is aimed at preventing a possible restenosis by virtue of its anti-proliferative action against smooth muscle cells.

The development of stent has been a major advance in the treatment of obstructive arteries. It was initially done for coronary artery disease with the introduction of balloon angioplasty during 1970s wherein a minimally invasive catheter was placed in arteries for their re-opening that had become narrowed with plaque, so restricting blood flow. The balloon was inflated inside artery to restart the proper blood flow.

This traditional method of balloon angioplasty was running with its limitations where in some cases the process would weaken the artery wall to an extent that once the balloon is deflated the artery would again get narrowed. Most vascular complications develop in less than 3 months after Liver transplantation, with the most common being HAS. Frequently, HAS is found mostly at the anastomosis between the donor and recipient artery and is asymptomatic in presentation but can eventually lead to biliary complications and strictures.

The etiology of HAS can be attributed to technical error, vessel redundancy or kinking, clamp injury, anastomotic ischemia, or acute rejection. Thus addressing this issue with the help of Drug Eluting Stents received a larger interest.

II. BARE METAL STENTS AND DRUG-ELUTING STENTS

Bare Metal Stents (BMS) were introduced in late 1990s to overcome the issues of angioplasty. It basically is an expandable mesh cylinder that is mounted on a balloon which when inserted carefully into an artery opens out. This stent doesn't let the artery to get narrowed down once the balloon gets deflated. Although the rate of restenosis had come down but it did not vanish away completely even with BMS.

This also brought in a new issue called 'thrombosis' wherein there is a blood clot that happens in the area of stent placement due to the immune system treating it as a 'foreign body' [5]. This thrombus in the artery could be hazardous and dangerous for life. Thus, in order to address the issue of restenosis Drug-eluting Stents (DES) were developed. DES are nothing but BMS coated with some drugs that would help stopping cell proliferation and thus the process of restenosis. It would take about 8-9 months for the drug to be released completely and then the chances of restenosis would be very less. It is evident that DES significantly reduce the incidence of restenosis compared with BMS, to levels of under 10 percent [6]. But with DES there was a new issue called late-

thrombosis wherein the blood clot appeared almost 1 year of stent placement. Thus the latest work in the field of DES is to overcome the problems of late-thrombosis. There is development of biodegradable polymers that breaks once the drug release is over and just the BMS is left. A very recent development in the stent technology is the polymer free stents where the drug gets directly released from the stent itself without any polymer being involved. Efficacy of such stents is under research and they are yet to be commercialized.

III. STENT BASED DRUG DELIVERY

Stent based drug delivery includes DES that usually has one or more biocompatible polymeric coatings surrounding stent struts and containing the therapeutic agent to be delivered. Latest DES are addressing the issue of In-stent Restenosis (ISR). The main processes of ISR include smooth muscle cell activation and replication in the site of injury. The best approach of stent based drug delivery system would be to deliver the appropriate concentration of effective agent to stop this process of restenosis further. Parameters that affect the rate of drug delivery are the thickness of the polymeric coatings and the diffusivity of the drug and the wall-coat interactions. The coating of stent struts can include two or more layers to modify the characteristics of drug delivery [7]. An ideal DES to achieve the best efficacy would be by controlling the geometrical thickness of coatings, the concentration of therapeutic agent.

A. Stent Designs

A study has shown how the various designs of stent has an effect on the drug distribution [8]. Configuration of struts in the stent has the direct impact on the drug delivered by DES [9]. The stent struts being near to vascular tissue doesn't guarantee the proper or sufficient drug delivery. In this study, even with the uniform concentration of drug at various depths of artery the homogenous drug distribution was not achieved [9]. The strut pattern, their number and their symmetric expansion showed a promising feature of homogenous drug distribution [9]. There are two types of stent design, open cell and closed cell [10]. A closed cell stent when deployed in a curved vascular segment, would expand in a uniform fashion with a constant cell spacing. An open cell stent has large variation in terms of surface coverage between the inner and outer curvatures in a curved vascular segment but promises better conformability than the closed cell stent at the cost of uniform drug distribution [10]. Most of the stents use the closed cell design prioritising the uniform drug distribution. In order to reach entire lesion, an optimal stent design should have a large stent surface area, a small cell gap, better conformability, flexible enough and with a minimal strut deformation post deployment.

B. Stent Coating

Stents can be coated with drugs using many methods. In few, the drugs can be directly bonded with the metal stent but in most of the cases the drug is bonded to a matrix polymer which reserves the drug within it intact while the stent is deployed in a vascular segment. The designs of polymer coating, their types and compositions are the deciding factors for the way that the drugs release and its kinetics [11]. There are organic and inorganic polymer coatings. All naturally occurring organic polymers are biocompatible. Most of the DES are coated with synthetic polymers; poly-n-butyl methacrylate and polyethylene-vinyl acetate with sirolimus and a poly (lactide-co- Σ -caprolactone) copolymer with paclitaxel eluting stents [12]. Phosphorylcholine is a naturally occurring phospholipid polymer with less potential to elicit inflammation and to interfere with re-endothelialization of the stent surface [13].

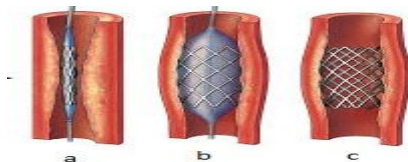


Fig. 1 (a) Insertion of Drug- Eluting Stent in Hepatic Artery with Stenosis (b) Balloon Inflation to expand the Stent (c) Balloon Deflation and Stent retention. DES starts releasing drugs for treating stenosis

C. Drugs Used

The general mechanism of action for any drugs used in these stents is to inhibit and stop the cell cycle progression using DNA synthesis. There is a process called 'mitosis' that is nothing but the process of cell division which gets hindered by using these drugs which possess the anti-inflammatory and anti-proliferative properties. Everolimus, sirolimus, tacrolimus (FK-506), ABT-578, interferon, dexamethasone, and cyclosporine all fall into this category. In this group, sirolimus and its derivatives were shown to reduce intimal thickening [14]. Dexamethasone-coated BiodivYsio stent also showed a mild to moderate benefit in reducing restenosis [15]. Paclitaxel has been approved for clinical use and ABT-578 also appears promising [16].

D. Stent Placement

The Stent would be placed with the help of a 0.014-inch wire that would cross the lesion in most cases where angioplasty balloons with 2-5mm diameter and 15-30mm length are inflated inside the stents [17]. In one of the cases as presented in a paper [18] the procedure of stent was carried out as: The left brachial artery was cannulated using a 4-French micropuncture kit and modified Seldinger technique. A 5-French 11-cm sheath was advanced into the artery. Using a 5-French pigtail catheter and J-wire, we obtained access to the descending aorta. The J-wire was removed and a 0.035-inch wire (Supra Core, Abbott Vascular, Abbott Park, IL) was left in the descending aorta. The pigtail catheter and the 5-French sheath were removed and a 6-French 55-cm sheath (Ansel, Cook Medical Inc., Bloomington, IN) was advanced to the abdominal aorta over the Supra Core wire. A 6-French multipurpose guide catheter was then used to selectively engage the celiac trunk and multiple angiographic images obtained. The patient was noted to have a 70–80% stenosis of hepatic artery at the anastomotic site. This is how the stent would be placed, practically there would be a lot of complications and difficulties while placing the stent. Proper alignment of stent struts to the vascular wall is very important for avoiding any other complications associated with the procedure.

IV. PROBLEMS FACED WITH STENT BASED DRUG DELIVERY

A. Incomplete stent apposition (ISA)

The misalignment between the stent struts and the vascular wall of the artery is termed as Incomplete Stent Apposition [19]. It is possible that this is due to either an initial incomplete deployment of stent during implantation or positive remodeling of vessel wall but other mechanisms like plaque regression, cell necrosis, apoptosis, and allergic reaction to drug [20, 8]. At times uneven stent strut distribution may also cause ISA

B. Financial Burden

The DES that are available commercially are not economical and it seems to be a burden on many patients. As of now one DES costs around \$3065-\$3195 [21]

V. CONCLUSIONS

The release of a substance in a living tissue for therapeutic purposes is a common practice in medicine nowadays, through drug delivery devices. In general, the mechanism of release is quite complex and depends on many concurrent biochemical, physical and individual factors. In recent years, new strategies for drug delivery, such as DES, are being developed and much effort in modelling is currently addressed to a deeper understanding of the complex drug elution mechanism. Proper placement of stents and reasonable number of struts, their expansion, the therapeutic drug itself, many such factors contribute towards the success of a DES in its very own task of delivering right amount of drug in right proportions. The researches that are going in this field definitely assure for better drug delivery devices and cost effective ones so that large set of population who are undergoing treatments should be able to afford and use it.

REFERENCES

- [1] Sabri SS, Saad WE, Schmitt TM, Turba UC, Kumer SC, Park AW, et al. Endovascular therapy for hepatic artery stenosis following liver transplantation. *Vasc Endovasc Surg* 2011;45:447-52.
- [2] Stagne BJ, Glanemann M, Nuessler NC, Settmacher U, Steinmuller T, Neuhaus P. Hepatic artery thrombosis after adult liver transplantation. *Liver Transpl* 2003;9:612-20
- [3] Busuttill R, Colonna JO, Hiatt JR, Brems JJ, el Khoury G, Goldstein LI, et al. The first 100 liver transplants at UCLA. *Ann Surg* 1987;206:387-99
- [4] R. M. Califf, Restenosis: The cost to society, *Am. Heart J.*, 130 (1995), 680–684.
- [5] Kunz JS, Turco MA. The DES Landscape in 2001: Future directions in drug-eluting stent design. *Cardiac Interventions Today*, January/February 2001, 48-51
- [6] Stone GW, Lansky AJ, Pocock SJ et al. Paclitaxel-Eluting Stents versus Bare-Metal Stents in Acute Myocardial Infarction. *N Engl J Med* 2009; 360:1946-1959
- [7] G. Acharya and K. Park, Mechanisms of controlled drug release from drug-eluting stents, *Advanced Drug Delivery Reviews*, 58 (2006), 387–401
- [8] Takebayashi H, Mintz GS, Carlier SG, et al. 2004. Nonuniform strut distribution correlates with more neointimal hyperplasia after Sirolimus-eluting stent implantation. *Circulation*, 110:3430–4.
- [9] Hwang CW, Wu D, Edelman ER. 2001. Physiological transport forces govern drug distribution for stent-based delivery. *Circulation*, 104:600–5
- [10] Rogers CDK. 2002. Drug-eluting stents: role of stent design, delivery vehicle, and drug selection. *Rev Cardiovasc Med*, 3(Suppl 5): S10–15
- [11] Sousa JE, Serruys PW, Costa MA. 2003a. New frontiers in cardiology: drug-eluting stents: part I. *Circulation*, 107:2274–9
- [12] Ratner BD. 1993. The blood compatibility catastrophe. *J Biomed Mater Res*, 27:283–7
- [13] Lewis AL, Tolhurst LA, Stratford PW. 2002. Analysis of a phosphorylcholine-based polymer coating on a coronary stent pre- and postimplantation. *Biomaterials*, 23:1697–706
- [14] Sousa JE, Costa MA, Sousa AG, et al. 2003. Two-year angiographic and intravascular ultrasound follow-up after implantation of sirolimus-eluting stents in human coronary arteries. *Circulation*, 107:381–3



- [15] Liu MW, Parks JM, Cox DA, et al. 2002. Interventional cardiovascular medicine, principles and practice. In: Vascular biology of mechanical intervention. 2nd ed. Philadelphia: Churchill Livingstone
- [16] Meredith I. 2003. ENDEAVOR I: 4-month angiographic and IVUS result [online]. Presented at Transcatheter Cardiovascular Therapeutic, Washington DC, USA, 16–21 Sept 2003. Accessed 27 Dec 2004. URL: http://www.tctmd.com/expert-presentations/multislide.html?product_id=5356.
- [17] Linda Le, MD, William Terral, MD, Nicolas Zea, MD, Hernan A. Bazan, MD, Taylor A. Smith, MD, George E. Loss, MD, Edward Bluth, MD, and W. Charles Sternbergh III, MD, New Orleans, La. Primary stent placement for hepatic artery stenosis after liver transplantation, [https://www.jvascsurg.org/article/S0741-5214\(15\)00955-6/pdf15](https://www.jvascsurg.org/article/S0741-5214(15)00955-6/pdf15)
- [18] Parmar H, Beard R, Mewissen MW, Shaikh A, Bajwa T. Use of coronary techniques in celiac and hepatic artery stenting in post-hepatic transplant patients. J Patient-Centered Res Rev. 2015;2:127-131. doi:10.17294/2330-0698.1196
- [19] Serruys PW, Degertekin M, Tanabe K, et al. 2002. Intravascular ultrasound findings in the multicenter, randomized, double-blind RAVEL (Randomized study with the sirolimus-eluting velocity balloonexpandable stent in the treatment of patients with de novo native coronary artery lesions) trial. Circulation, 106:798–803
- [20] Lemos PA, Saia F, Lighthart JM, et al. 2003. Coronary restenosis after sirolimus-eluting stent implantation: morphological description and mechanistic analysis from a consecutive series of cases. Circulation, 108:257–60
- [21] Cohen DJ, Bakhai A, Shi C, et al. 2003. Cost-effectiveness of sirolimus eluting stents for the treatment of complex coronary stenosis: results from the randomized SIRIUS trial [abstract]. J Am Coll Cardiol, 41(Suppl):32A.