



iJRASET

International Journal For Research in
Applied Science and Engineering Technology



INTERNATIONAL JOURNAL FOR RESEARCH

IN APPLIED SCIENCE & ENGINEERING TECHNOLOGY

Volume: 8 Issue: VI Month of publication: June 2020

DOI: <http://doi.org/10.22214/ijraset.2020.6133>

www.ijraset.com

Call:  08813907089

E-mail ID: ijraset@gmail.com

Peri-implantitis: A Curse to Implants

Dr. Navneet Kour¹, Dr. Sarish Latief², Dr Nadia Irshad³, Dr Kousain Sehar⁴, Dr. Adeel Ahmed Bajjad⁵, Dr. Burhan Atlaf Misgar⁶, Dr. Manju Tagra⁷, Dr. Hilal Ahmad Hela⁸

¹MDS student Department Of Periodontology and Implantology BRS Dental College and Hospital.

²MDS student Dept Of Oral and Maxillofacial Surgery, BRS Dental College and Hospital Sultanpur Panchkula.

³MDS student Dept of Paedodontics and Preventive Dentistry, BRS Dental College and Hospital Sultanpur Panchkula

⁴MDS student Dept of Periodontology and Implantology, BRS Dental College and Hospital Sultanpur Panchkula.

⁵MDS student Dept of Orthodontics, Kothiwal Dental College and Research Center Moradabad, Uttar Pardesh.

⁶MDS student Dept of Paedodontics and Preventive Dentistry Guru Nanak Dev Dental College and Research Institute, Sunam.

⁷MDS student Dept of Paedodontics and Preventive Dentistry, BRS Dental College and Hospital Sultanpur Panchkula.

⁸MDS student Dept of prosthodontic, Crown and Bridge and Implantology, GDC, Srinagar.

Abstract: *Peri-implant implant speaks to genuine inflammation after implant treatment, which influences both the incorporating hard and delicate tissue. Peri-implantitis can cause the loss of implant without multilateral anticipation and treatment ideas. Nonstop registration with assessment and end of hazard factors including smoking, fundamental maladies and periodontitis are viable precautionary measures. Type and structure of implant surface are of most extreme significance notwithstanding parts of osseointegration. Different moderate and careful methodologies are accessible for the treatment of peri-embed malady. Mucositis and moderate sorts of peri-implantitis can clearly be dealt with successfully utilizing traditionalist techniques. These incorporate the utilization of different manual removals, laser-bolstered frameworks, which can be utilized what's more of nearby or fundamental anti-microbials and is conceivable to recapture osseointegration. In cases with cutting edge peri-implantitis careful treatments are more straightforward than moderate methodologies. Resective medical procedure is regularly directed for the disposal of peri-implant injuries, while regenerative treatments are likewise appropriate for imperfection filling. The point of this review is to flexibly a rundown about conclusion, anticipation and treatment of peri-embed illness for experts.*

Keywords: *Etiology, Histopathology, Mucositis, Periimplantitis, Periodontal Diseases*

I. INTRODUCTION

One of the key factors for the long-term success of oral implants is that the maintenance of healthy tissues around them. This depends on a biological balance between inflammatory and regenerative processes, ultimately with the latter as a dominant component. A reason impact connection between bacterial plaque gathering and the improvement of incendiary changes in the delicate tissues encompassing oral inserts has been appeared in the ongoing past.. If the inflammatory process exceeds the regenerative capacity, implant failure may occur.¹

Peri-implant diseases affect the peri-implant mucosa only and/or also involve the supporting bone. Peri-implantitis is an inflammatory process which affects the tissues around an osseointegrated implant in function, resulting in the loss of the supporting bone, and often associated with bleeding, suppuration, increased probing depth, mobility and radiographical bone loss. Literature has shown that the inflammation is more pronounced and the inflammatory process goes deeper and faster around the dental implant than around the adjacent natural tooth.² Implants have a less effective natural tissue barrier than natural teeth and are less resistant to infection.³ There are a number of factors which may contribute to the development and progression of peri-implantitis. These include patient factors (e.g. periodontally susceptible individuals, smokers, diabetics, alcohol consumption, oral hygiene, presence of keratinized mucosa and genetic traits) and implant related factor (e.g. implant design and surface characteristics).^{4,5}

The recognition and treatment of peri-implantitis around functioning implants is a major challenge for the clinician. Correct diagnosis of peri-implant disease is critical for appropriate management of peri-implant disease. Presence of probing depth, bleeding on probing, and suppuration should be assessed regularly. Radiographs are required to gauge supporting bone levels around implants. The long-term goals within the treatment of peri-implantitis are to arrest the progression of the disease and to realize a maintainable site for the patient's implant. Attempts are made to work out the optimal treatment protocol for achievement of complete resolution of peri-implantitis. In addition to the resolution treatment may also include regeneration of lost tissue and re-establishment of osseointegration along previously contaminated implant surfaces. Conservative, resective and regenerative factors in the treatment of peri-implantitis have been investigated in conjunction with various methods of surface decontamination.

Understanding of these factors would help the clinician to arrive at an early diagnosis, provide the patient with successful treatment outcomes and monitor the response to therapy.

One of the key components for the drawn out achievement of oral implant is the support of solid tissues around them. This relies upon an organic harmony among fiery and regenerative procedures, at last with the last as a prevailing segment. A reason impact connection between bacterial plaque amassing and the advancement of provocative changes in the delicate tissues encompassing oral inserts has been appeared in the ongoing past. On the off chance that the fiery procedure surpasses the regenerative limit, embed disappointment may occur.¹

Peri-implant diseases influence the peri-implant mucosa just as well as likewise include the supporting bone. Peri-implantitis is a fiery procedure which influences the tissues around an osseointegrated implant in work, bringing about the loss of the supporting bone, and frequently connected with dying, decay, expanded examining profundity, portability and radiographical bone misfortune. Writing has indicated that the irritation is progressively articulated and the fiery procedures goes further and quicker around the dental implant than around the nearby common tooth.² Implants have a less powerful normal tissue boundary than regular teeth and are less impervious to infection.³ There are various elements which may add to the turn of events and movement of peri-implantitis. These incorporate patient components (for example periodontally susceptible individuals, smokers, diabetics, alcohol consumption, oral hygiene, presence of keratinized mucosa and genetic traits) and implant related factor (for example implant design and surface characteristics).^{4,5}

The acknowledgment and treatment of peri-implantitis around working implant is a significant test for the clinician. Right determination of peri-implant disease is basic for fitting administration of peri-implant diseases. Nearness of examining profundity, seeping on testing, and decay ought to be evaluated normally. Radiographs are required to check supporting bone levels around inserts. The drawn out objectives inside the treatment of peri-implantitis are to capture the movement of the malady and to understand a viable site for the patient's embed. Endeavors are made to work out the ideal treatment convention for accomplishment of complete goals of peri-implantitis. Notwithstanding the goals treatment may likewise incorporate recovery of lost tissue and re-foundation of osseointegration along recently polluted implant surfaces. Preservationists, resective and regenerative factors in the treatment of peri-implantitis have been researched related to different techniques for surface disinfecting. Comprehension of these elements would assist the clinician with arriving at an early finding, furnish the patient with effective treatment results and screen the reaction to treatment.

Table:1 Difference between the oral mucosa around the tooth and implant.⁶⁻⁹

| COMPONENTS | ORAL MUCOSA AROUND NATURAL TOOTH /GINGIVA | PERI-IMPLANT MUCOSA |
|-------------------|--|---|
| EPITHELIUM | Natural gingival epithelium: oral epithelium, oral sulcular epithelium and junctional epithelium. | Epithelium around implant: oral epithelium, peri-implant sulcular epithelium, peri-implant epithelium (PIE), |
| | Oral sulcular epithelium It is keratinized, similar to the peri-implant sulcular epithelium. The basal layers of the oral sulcular epithelia form general epithelial-connective barriers, including basement membrane and hemidesmosomes, which join the epithelium to the sub-epithelial tissue. | Peri-implant sulcular epithelium The peri-implant sulcular epithelium imparts histological and topological properties to the characteristic oral sulcular epithelium. This epithelium, which shapes a piece of the internal embed minor epithelium, frames a neckline round the peri-embed sulcus. The peri-embed sulcular epithelium is keratinized, practically like the oral epithelium, yet in addition contains keratohyaline granules, showing a keratinized |
| | JUNCTIONAL EPITHELIUM It gives the connection between the tooth and the gingiva. In the event that the free gingiva is extracted after the tooth has completely emitted, another junctional epithelium, vague from that discovered after tooth emission, will create during mending. | PIE The PIE, the opposite a part of the inner-implant epithelium, demonstrates unique and specific characteristics, forming a solid transmucosal interface round the implant. The topological and structural features of the PIE resemble those of the tooth-enamel interface epithelium, the junctional epithelium, suggesting a crucial function for the transmucosal region around dental implants in biological sealing and defence. |
| CONNECTIVE TISSUE | In the mesenchymal tissue present at a tooth, from the cementum, coarse dentogingival and dentoalveolar collagen fibre bundles projected in lateral, coronal, and apical directions. | At the implant site, the collagen fibre bundles were orientated in an entirely different manner. Here the fibres are invested in the periosteum at the bone crest and projected in directions parallel to the implant surface. |
| | More fibroblast and vascular structure are seen in connective tissue present at natural tooth. The connective tissue in the supracrestal area at implants was found to contain more collagen fibres, but fewer fibroblasts and vascular structures. | Connective tissue attachment between the titanium surface and the connective tissue is established and maintained by fibroblasts |

A. Vascular Supply

Berglundh et al observed that the vascular system of the peri-implant mucosa originated solely from the large suprapariosteal blood vessel on the outside of the alveolar ridge. This vessel gave off branches to the supra-alveolar mucosa and form.

- 1) The capillaries beneath the oral epithelium and
- 2) The vascular plexus located immediately lateral to the barrier epithelium.¹⁰

B. Innervation of PIE by Sensory Nerve Fibers

The peri-implant mucosa is supplied with sensory nerves containing calcitonin gene related peptide and substance P. PIE consists of innervation which is denser than in other parts of the epithelium (peri-implant sulcular epithelium and oral epithelium). Neurokinin-1 receptors, (receptors for substance P), are expressed on the extra- and intra-epithelial nerve fibers, endothelial cells and PIE cells. These receptors also are localized in neutrophils invading into the intercellular spaces between PIE cells.⁶

II. CLASSIFICATION

There is no normalized grouping which separates between the changed level of peri-implantitis in this manner prompting disarray when deciphering the consequences of studies assessing the predominance, treatment and result of treatment.

Table -2 Spiekermann classification of Peri-implantitis¹¹

| | |
|---------|---|
| Class-1 | Slight horizontal bone loss with minimal peri-implant defect |
| Class-2 | Moderate horizontal bone loss with isolated vertical defect |
| Class-3 | Moderate horizontal/vertical bone loss with circular bony defect |
| Class-4 | Advanced bone loss with broad, circumferential vertical defect, as well as loss of oral and/or vestibular bony wall |

Table -3 Staurt J. Froum and Paul S. Rosen classification of Peri-implantitis¹²

| | |
|----------|--|
| Early | PD \geq 4 mm .Bone loss < 25% of the implant length |
| Moderate | PD \geq 6 mm .Bone loss 25% to 50% of the implant length |
| Advanced | PD \geq 8 mm. Bone loss > 50% of the implant length |

III. CLINICAL FEATURES

Peri-implantitis represents a clinical condition that includes the presence of inflammatory lesion in the peri-implant mucosa and loss of peri-implant bone. Therefore, diagnosis of peri-implantitis requires detection of both bleeding on probing (BOP) and bone loss on radiographs.

Following are the typical signs and symptoms of peri-implantitis lesions:

- A. Bleeding on gentle probing using blunt instrument suppuration from the pocket.
- B. Radiological evidence for the presence of vertical destruction of crestal bone. The defect is usually in the shape of a saucer, while the bottom retains perfect osseointegration. In some cases a wedge-shaped defects is found around the implant. Whether specific patterns of marginal bone loss indicate a selected underlying cause isn't known. Bone destruction may follow without any visible signs of implant mobility until osseointegration is completely lost.¹³
- C. Continuous peri-implant radiolucency.
- D. Vertical bone destruction associated with peri-implant pocket formation.
- E. Tissues may or may not be swollen. Hyperplasia is frequently seen when and if the implants are located in an area with non-keratinized mucosa or if the supra-structure is an over-denture.
- F. Pain is not found to be a typical feature of peri-implantitis.

IV. HISTOPATHOLOGY

Microscopic examination of tissues harvested from peri-implantitis sites in human consistently revealed that the mucosa contained large inflammatory cell infiltrates. Sanz *et al.*¹⁴ Piattelli¹⁵ analyzed soft tissue from sites where the implants had been removed due to peri-implantitis, “an inflammatory infiltrate, composed of macrophages, lymphocytes and plasma cells, was found in the connective tissue around the implants”. Berglundh *et al.* reported that numerous neutrophils granulocytes (polymorphonuclear leukocytes) were present in the lesions. Such cells occurred not only in the pocket epithelium and associated areas of the lesions, but also in peri-vascular compartments in the centre of the infiltrate, that is distant from the implant surface. In the apical part of the lesion, the inflamed connective tissue appeared to be in direct contact with the biofilm on the implant surface.¹⁵

Immunohistochemical techniques have also been used to evaluate differences between peri-implantitis and periodontitis lesions. Kontinen *et al* reported that the number of cells positive for interleukin-1 alpha (IL-1 α) and IL-6 was greater and the number of tumor necrosis factor alpha (TNF- α)–positive cells lesser in peri-implantitis than in periodontitis lesions.¹⁶

Thus, Peri-implantitis lesions are poorly encapsulated, extend to the marginal bone tissue, and may, if allowed to progress, lead to the loss of the implant. Neutrophils are found in large quantities in the peri-implantitis lesion and epithelial lining absence between the lesion and the biofilm, indicate that the peri-implantitis lesions have features that are different from those of periodontitis lesions. Progression of peri-implantitis is more pronounced at implants with rough than at those with smooth surfaces.

V. DIAGNOSIS

Peri-implant diagnostic procedures can serve several functions:

- 1) Screening of peri-implant disease or factor for increasing the risk to develop an undesirable condition,
- 2) Differential diagnosis of peri-implantitis and peri-implant mucositis,
- 3) Treatment planning and
- 4) Evaluation of therapy and monitoring.

Table-4: main diagnostic differences between peri-implant mucositis and peri-implantitis(Chen &Derby)¹⁷

| Clinical parameters | Peri-implant mucositis | Peri-implantitis |
|-------------------------|------------------------|------------------|
| Increased probing depth | +/- | + |
| BOP | + | + |
| Suppuration | +/- | + |
| Mobility | - | +/- |
| Radiographic bone loss | - | + |

A. Diagnostic Parameters

- 1) *Peri-implant Radiography*: The preservation of marginal bone height is considered crucial for implant maintenance and is often used as a primary success criterion for implant systems. Vertical bone loss of less than 0.2 mm annually following the implant’s first year of service has been proposed as one of the major criteria for success. For the accurate assessment of bone level changes, longitudinal series of standardized radiographs are required. Minute changes of bone level or density can be detected using re-producible projection geometry for the X-ray beam, which is provided by an appropriate aiming device. It is important to note that the mean annual bone height changes in the range of 0.1 mm are only mathematically determined and cannot be detected by comparison of two radiographs from a single implant.¹⁸
- 2) *Peri-implant Probing*: In addition to the evaluation of bone levels on radiographs, peri-implant probing has been suggested as a useful diagnostic procedure. Probing the peri-implant sulcus with a blunt, straight periodontal probe allows the assessment of the following parameters:
 - a) Peri-implant probing depth;
 - b) Distance between the soft tissue margin and a reference point on the implant (measurement of soft tissue hyperplasia or recession) ;
 - c) Bleeding after probing; and
 - d) Exudation and suppuration from the peri-implant space.

Effective implant for the most part permits test entrance of around 3 mm. It has been shown that the magnitude of probe penetration into a periodontal pocket depends on the force applied to the instrument. The mean distance between the probe tip and the peri-implant bone crest amounted to 0.75 \pm 0.60 mm at 0.25N probing force.¹⁹ Standardized probes such as the Audio Probe, the TPS Probe or the HAWE Click Probe may be recommended.

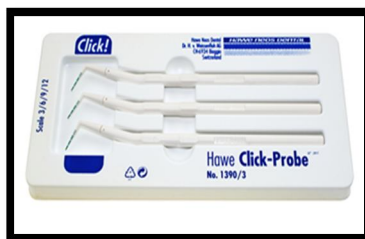

Fig 1: The TPS Probe Or The Hawe Click Probe

- 3) **Mobility:** Implant mobility is found due to lack of osseointegration. No matter about the condition of the peri-implant tissues, implants may still appear to be immobile due to remaining direct bone-to-implant contact. Mobility is thus insensitive in detecting the early stages of peri-implant disease. For the interpretation of low degrees of mobility, an electronic device has been proposed, which was originally designed to measure the damping characteristics of the periodontium of natural teeth (Periotest®, Siemens AG, Bensheim, Germany).²⁰
- 4) **Suppuration:** Histological assessments of periodontal tissues show an invasion with neutrophils at whatever point disease is present.¹⁵ High quantities of leukocytes have been appeared with implants that have increased gingival irritation.
- 5) **Clinical Indices²¹:** swelling and redness of the peripheral tissues have been accounted for from peri-implant contaminations notwithstanding pocket formation, suppuration and bleeding. Acknowledgment of these signs has been viewed as significant in the determination of periodontal illness.
- 6) **Peri-implant Crevicular fluid (PICF) and Saliva Analysis:** Levels of biochemical mediators secreted into the PICF have been identified as a diagnostic marker to monitor peri-implant health. Markers in PICF including cytokines, enzymes, and proteases have been investigated. More recently saliva samples, with the advantage of being non-invasive and simpler to collect than PICF, have been evaluated.²²
- 7) **Microbiology:** high levels of *Porphyromonas gingivalis*, *p intermedia* and *Actinobacillus actinomycetemcomitans* have increased the risk of attachment loss in maintenance patients.²³ The presence of different forms of peri-implant disease, including few infections and nonbacterial failures, shows that microbiological tests may used as an important tools for the differential diagnosis of peri-implantitis and treatment planning. It is biologically sound and good medical practice to base systemic antimicrobial therapy on appropriate microbiological data.²⁴

The decision process for peri-implant diagnosis²⁵

It is suggested that the clinician start the diagnostic procedure with the following question (Fig. 1):

- a) Are there peri-implant pockets deeper than 3 mm?
- b) Is it peri-implantitis?
- c) Is there evidence for a specific (microbial) cause of this condition?

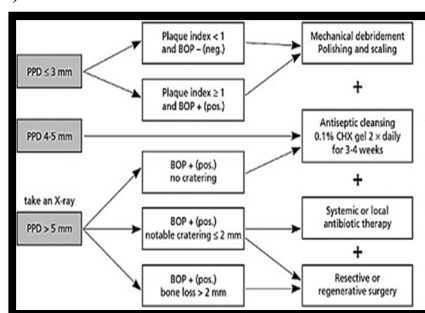


Figure 1: The decision process for peri-implant diagnosis

VI. MANAGEMENT

Peri-implant diseases are important entities as a result of their high prevalence and the lack of a standard mode of therapy.

Treatment approaches for peri-implantitis:

The evaluation has been divided into two parts:

- 1) Nonsurgical therapy of peri-implantitis; and
- 2) Surgical therapy of peri-implantitis.

A. *Peri-Implantitis Nonsurgical Therapy*

The basis for peri-implantitis non-surgical therapy is infection control through debridement of the implant surface, with the aims of debriding the adhered biofilm and reducing the bacterial load below the threshold level for causing disease.

Mechanical debridement around dental implants encounters some specific characteristics:

- 1) The absence of periodontal ligament;
- 2) A variable (more/less rough) implant surface; and
- 3) Different types of abutment connection.

These factors can jeopardize not only the professional therapy, but also the patient's self-performed hygiene because these characteristics may facilitate biofilm formation when the surfaces become exposed to the oral environment.²⁶

B. *Peri-Implantitis Nonsurgical Therapy: Mechanical Or Automatic Debridement*

Objectives and technologies for the mechanical debridement of implant surfaces (curettes, air-abrasive devices, ultrasonic devices and lasers) have been evaluated for the treatment of peri-implantitis. Different types of curettes have been studied, mainly those made of carbon fibre or titanium, and most of the protocols included an adjunctive polish with a rubber cup and a polishing paste.²⁷

As of recent, a fueled air-abrasive framework, in light of a low-grating amino-corrosive glycine powder, has been exhibited as a successful strategy for biofilm expulsion from the root surface, without harming hard and delicate tissues and it has been suggested for debriding insert surfaces.²⁸

Different tip modifications have been proposed, such as carbon fiber, silicone or plastic to remove calculus and biofilms without altering the implant surface.²⁷ Another modification to the conventional ultrasonic device is the Vector-system, in which the horizontal vibration is converted by a resonating ring into a vertical vibration, resulting in a parallel movement of the working tip to the surface.

The use of lasers has also been proposed in the treatment of peri-implantitis as a result of their anti-infective, physical and ablation properties. The erbium-doped yttrium aluminium garnet laser has shown the highest potential for use in the treatment of peri-implantitis as a result of its ability to remove subgingival plaque and calculus efficiently without significantly damaging the implant surface.²⁹

C. *Peri-Implantitis Nonsurgical Therapy: Adjunctive Use Of Antimicrobial Products*

Adjunctive therapies, such as antiseptics and antibiotics, have been proposed to improve the results of nonsurgical debridement as reduction of bacterial loads to levels compatible with tissue health is difficult to accomplish using mechanical means only.³⁰

Chlorhexidine-based products, as gels, irrigation and/or rinses, and in different formulations and regimes, have been reported. Examples include:

- 1) Frequent regular irrigation of the peri-implant pocket with 0.2% chlorhexidine in one session;
- 2) Single application of 1% chlorhexidine gel with a disposable syringe;
- 3) Repeated application of 1% chlorhexidine gel at treatment and at 30 and 90 days after treatment²⁸;
- 4) The combination of pocket irrigation with 0.2% chlorhexidine + 0.2% chlorhexidine gel, applied subgingivally in each implant at the day of intervention and the use of 0.2% chlorhexidine mouth rinse, twice daily for 2 weeks; and
- 5) Pocket irrigation with 0.12% chlorhexidine + 1% chlorhexidine gel.

Different protocols using locally or systemically delivered antimicrobials have been evaluated:

- a) A single-unit dose of 1 mg of minocycline and 3 mg of poly (glycolide-co-dl-lactide) placed submucosally at each treatment site, at treatment and 30 and 90 days after treatment;
- b) A single dose of 1 mg of minocycline microspheres;
- c) 1 mg of minocycline microspheres at treatment and 180 and 270 days after treatment;
- d) Or topical irrigation with a solution containing 8.5% by weight of doxycycline and 37% by weight of poly-dl-lactide dissolved in a biocompatible carrier of n-methyl-2-pyrrolidone.³¹

D. *Peri-implantitis surgical therapy*

The treatment of peri-implantitis should focus on bone recovery and the fulfillment of re-osseointegration. This wonder of direct issue that remains to be worked out contact on a formerly infected implant surface has been reported in preclinical models however has never been shown in humans.³²

In this way the two overlap reason of the careful treatment of peri-implantitis:

- 1) To improve implant surface clean-capacity; and
- 2) To alter the life systems of delicate and hard peri-implant tissues so as to get re-osseointegration.

E. *Peri-Implantitis Surgical Therapy: Decontamination Of The Implant Surface*

- 1) *Mechanical Decontamination:* Physical removal of hard- and soft-tissue deposits on the contaminated exposed implant surfaces are the procedures included. Instruments for mechanical debridement usually include curettes, ultrasonic devices with special tips and air-powder abrasive systems. The advantages and limitations of these systems have already been described when used in nonsurgical therapy. A second, and more aggressive, approach has been proposed, consisting of smoothening of the implant surface (and thus removing the rough surface of the implant), resulting in a polished smooth surface more amenable for oral-hygiene practices carried out with burs and stones under copious irrigation because of rise in temperature and an extensive local contamination with titanium.³³
- 2) *Chemical Decontamination:* The rationale for the use of chemical treatments is to disinfect/decontaminate the implant surface by direct application of appropriate substances. Citric acid, hydrogen peroxide, chlorhexidine and/or saline have been utilized, and all have given similar results in experimental studies.
- 3) *Lasers:* Lasers have also been used to decontaminate the implant surface, although the scientific literature often failed to find clinical benefits. Schwarz et al. noticed that erbium lasers yielded significant advantages in terms of bleeding on probing and clinical attachment level; however, no differences were noted when compared with conventional mechanical treatment. No differences between the use of lasers and conventional treatment were noted with a CO₂ laser as adjunct to both resective and reconstructive techniques.³⁴

F. *Peri-implantitis Surgical Therapy: Surgical Techniques*

Various surgical techniques have been recommended, depending on the final objective of the surgical intervention:

- 1) Access for cleaning and purification of the implant surface (access flaps)
- 2) Access for cleaning and decontamination plus exposure of the affected surfaces for cleaning (apically repositioned flaps); and
- 3) Access for cleaning plus aiming for bone regeneration and re-osseointegration (regenerative techniques).
- a) *Access Flap Surgery:* The objective of this flap surgical intervention is to conserve and to maintain all the soft tissues around the affected implant and to focus mainly on the decontamination of the implant surface. Usually, intra-crevicular incisions are made around the affected implants and mucoperiosteal flaps are raised both buccally and palatally/lingually. Degranulation of the peri-implant inflamed tissues is best accomplished with titanium curettes and implant surface decontamination is performed. Finally, the flaps are repositioned and adequately sutured. As this technique aims to maintain the position of the soft-tissue margin around the implant neck, this can only be attained when the peri-implant bone loss is shallow.
- b) *Apically Positioned Flaps:* This surgical approach has been advocated in order to enhance self-performed oral hygiene and reduce the pockets around the affected implants. Technically, a reverse beveled incision is designed dependent on the probing pocket depth and the width and the thickness of the peri-implant mucosa. Vertical releasing incisions may be needed in order to position the flap apically. Mucoperiosteal flaps are raised both buccally and palatally/lingually. The collar of the affected tissues is then removed and the implant surfaces are thoroughly decontaminated. Carefully performed osteoplasty using bone chisels, is often required. Finally, the flaps are sutured in order to leave the previously affected part of the implant exposed to the oral cavity. Implantoplasty in order to smoothen the exposed part and to decrease the postsurgical contamination of the implant surfaces have also been suggested. The technique is indicated for peri-implantitis cases with suprabony defects or a one-wall intrabony defect.³⁵
- c) *Regenerative Surgical Techniques*

Regenerative approaches have two main objectives:

- i) To support the tissue measurements during the mending procedure, maintaining a strategic distance from downturn of the mucosa.
- ii) To enhance the chance of obtaining re-osseointegration, using reconstructive and regenerative techniques/materials.

Intracrevicular incisions are usually performed in order to maintain the total amount of soft tissues. After elevation of buccal and lingual periosteal flaps, degranulation of the defect is performed using titanium instruments. After purification of the implant surface, a graft is set around the implant, filling the intrabony part of the deformity. Grafting might be performed with either autologous bone or bone substitutes. The graft might be secured with a resorbable or a nonresorbable layer. At last, the folds are coronally situated and stitched so as to decide mending, with either a nonsubmerged or a lowered methodology³⁶

VII. CONCLUSION

Peri-implant diseases are irresistible in etiology and like periodontal disease in being started by dental plaque. There gives off an impression of being a high predominance with a combined increment with time in work. Smoking, poor oral cleanliness and corresponding periodontal sickness comprise the most critical hazard factors. Hazard evaluation and ordinary observing of peri-implant tissue in contrast with gauge parameters and suitable steady consideration are critical to save clinical wellbeing around inserts. Once analyzed, peri-implantitis destinations must be evaluated for conceivable treatment immediately to keep away from the danger of quick bone misfortune. Considering the way that anticipated re-osseointegration is yet a test, great supragingival plaque control, cleansable reclamations, exacting steady treatment systems are of outright significance for forestalling peri-implant infection.

REFERENCES

- [1] Iacono VJ. Dental implants in periodontal therapy. J Periodontol. 2000;71(12):1934-1942.
- [2] Lindhe J, Berglundh T et al. experimental breakdown of peri-implant and periodontal tissue- A study in the beagle dog. Clin Oral Implant Res 1992;3:9-16.
- [3] Meffert RM. The soft tissue interface in dental implantology. J Dent Educ 1988;52:810-811.
- [4] LJA Heitz-Mayfield. Diagnosis and management of peri-implant disease. Aust dent J. 2008;53(1):S43-S48.
- [5] Heitz-Mayfield LJA. Peri-implant diseases: diagnosis and risk indicators. J Clin Periodontol.2008;35(8): 292-304.
- [6] Yamasaki A, Nikai H, Niitani K, Ijuhin N. Ultrastructure of the junctional epithelium of germfree rat gingiva. J Periodontol. 1979; 50:641-648.
- [7] Berglundh T, Lindhe J, Ericsson R, Marinello CP, Liljenberg B & Thomsen P. The soft tissue barrier at implants and teeth. Clinical Oral Implant Research.1991; 2: 81-90.
- [8] Ikeda H, Yamaza T, Yoshinari M, Ohsaki Y, Ayukawa Y, Kido MA, Inoue T, Shimono M, Koyano K, Tanaka T. Ultrastructural and immunoelectron microscopic studies of the peri-implant epithelium-implant (Ti-6Al-4V) interface of rat maxilla. J Periodontol 2000;71:961-973.
- [9] Schroeder HE (1986) Gingiva. In: Oksche A, Vollrath L (eds) Handbook of microscopic anatomy, vol. 5, The periodontium, pp. 233-323.
- [10] Berglundh T, Lindhe J, Jonsson K & Ericsson I. The topography of the vascular system in the periodontal & peri-implant tissues dog. Journal of Clinical Periodontology.1994; 21:189-193.
- [11] Spiekman H. peri-implant pathology. In Rateitschak KH & Wolf HF. Color atlas of Dental Medicine- Implantology, 1st edition, pp 317-328. Stuttgart, New York: George Thieme Verlag, 1995.
- [12] Stuart J, Froum, Paul S. Rosen. A Proposed Classification for Peri-Implantitis. Int J Periodontics Restorative Dent 2012;32:533-540.
- [13] Adell R, Lekholm U, Rockler B, Brånemark P-I. A 15-year study of osseointegrated implants in the treatment of the edentulous jaw. Int J Oral Surg 1981; 10: 387-416.
- [14] Sanz, M., Aladez, J., Lazaro, P. et al. (1991). Histopathologic characteristics of peri-implant soft tissues in Branemark implants with two distinct clinical and radiological patterns. *Clinical Oral Implants Research* 2, 128-134.
- [15] Gualini, F. & Berglundh, T. (2003). Immunohistochemical characteristics of inflammatory lesions at implants. *Journal of Clinical Periodontology* 30, 14-18.
- [16] Kontinen, Y.T., Lappalainen, R., Laine, P. et al. (2006). Immunohistochemical evaluation of inflammatory mediators in failing implants. *International Journal of Periodontics and Restorative Dentistry* 26, 135-141.
- [17] Chen S, Darby I. Dental implants: Maintenance, care and treatment of peri-implant infection. Aust Dent J 2003;48:212-220, quiz 263.
- [18] Lekholm U, Adell R, Lindhe J, Brånemark P-I, Eriksson B, Rockler B, Lindvall A-M, Yoneyama T. Marginal tissue reactions at osseointegrated titanium fixtures. Int J Oral Maxillofac Surg 1986; 15: 53-61.
- [19] Mombelli A, Mericske-Stern R. Microbiological features of stable osseointegrated implants used as abutments for overdentures. Clin Oral Implants Res 1990; 1: 1-7.
- [20] Teerlink J, Quirynen M, Darius P, van Steenberghe D. Periotest? an objective clinical diagnosis of bone apposition toward implants. Int J Oral Maxillofac Implants. 1991; 6: 55-61.
- [21] Mühlemann HR, Son S. Gingival sulcus bleeding - a leading symptom in initial gingivitis. Helv Odontol Acta 1971; 15: 107-113.
- [22] Liskmann, S., Zilmer, M., Vihalemm, T., Salum, O. & Fischer, K. (2004) Correlation of peri-implant health and myeloperoxidase levels: a cross-sectional clinical study. *Clinical Oral Implants Research* 15, 546-552.
- [23] Bragd L, Dahl Cn G, Wikstrom M, Slots J. The capability of *Actinobacillus actinomycetemcomitans*, *Bacteroides gingivalis* and *Bacteroides intermedius* to indicate progressive periodontitis; a retrospective study. J Clin Periodontol 1987; 14: 95-99.
- [24] Rams TE, Feik D, Slots J. Staphylococci in human periodontal diseases. Oral Microbiol Immunol 1990; 5: 29-32.
- [25] Mombelli A, Lang N. The diagnosis and treatment of peri-implantitis. Periodontology 2000, Vol. 17, 1998, 63-76
- [26] Renvert S, Polyzois I, Claffey N. How do implant surface characteristics influence peri-implant disease? J Clin Periodontol 2011; 38(Suppl. 11): 214-222
- [27] Persson GR, Samuelsson E, Lindahl C, Renvert S. Mechanical non-surgical treatment of peri-implantitis: a single-blinded randomized longitudinal clinical study. II. Microbiological results. J Clin Periodontol 2010; 37: 563-573.
- [28] Schar D, Ramseier CA, Eick S, Arweiler NB, Sculean A, Salvi GE. Anti-infective therapy of peri-implantitis with adjunctive local drug delivery or photodynamic therapy: sixmonth outcomes of a prospective randomized clinical trial. Clin Oral Implants Res 2013; 24: 104-110.
- [29] Takasaki AA, Aoki A, Mizutani K, Kikuchi S, Oda S, Ishikawa I. Er: YAG laser therapy for peri-implant infection: a histological study. Laser Med Sci 2007; 22: 143-157.
- [30] Renvert S, Roos-Jansaker AM, Lindahl C, Renvert H, Persson GR. Infection at titanium implants with or without a clinical diagnosis of inflammation. Clin Oral Implants Res 2007; 18: 509-516.
- [31] Buchter A, Kleinheinz J, Meyer U, Joos U. Treatment of severe peri-implant bone loss using autogenous bone and bioabsorbable polymer that delivered doxycycline (Atridox). Br J Oral Maxillofac Surg 2004; 42: 454-456.



- [32] Persson LG, Berglundh T, Lindhe J, Sennerby L. Re-osseointegration after treatment of peri-implantitis at different implant surfaces. An experimental study in the dog. Clin Oral Implants Res 2001; 12: 595–603.
- [33] Teughels W, Van AN, Sliepen I, Quirynen M. Effect of material characteristics and/or surface topography on biofilm development. Clin Oral Implants Res 2006; 17(Suppl. 2): 68–81.
- [34] Deppe H, Horch HH, Neff A. Conventional versus CO2 laser-assisted treatment of peri-implant defects with the concomitant use of pure-phase beta-tricalcium phosphate: a 5-year clinical report. Int J Oral Maxillofac Implants 2007;22: 79–86.
- [35] Romeo E, Lops D, Chiapasco M, Ghisolfi M, Vogel G. Therapy of peri-implantitis with resective surgery. A 3-year clinical trial on rough screw-shaped oral implants. Part II: radiographic outcome. Clin Oral Implants Res 2007; 18:179–187.



10.22214/IJRASET



45.98



IMPACT FACTOR:
7.129



IMPACT FACTOR:
7.429



INTERNATIONAL JOURNAL FOR RESEARCH

IN APPLIED SCIENCE & ENGINEERING TECHNOLOGY

Call : 08813907089  (24*7 Support on Whatsapp)